

Laxity Testing of the Shoulder

A Review

Michael Bahk,* MD, Ekavit Keyurapan,* MD, Atsushi Tasaki,* MD, Eric L. Sauers,[†] PhD, ATC, and Edward G. McFarland,*[‡] MD

From the *Division of Sports Medicine and Shoulder Surgery, Department of Orthopaedic Surgery, Johns Hopkins University, Baltimore, Maryland, and the [†]Department of Sports Health Care, Arizona School of Health Sciences, A. T. Still University, Phoenix, Arizona

Laxity testing is an important part of the examination of any joint. In the shoulder, it presents unique challenges because of the complexity of the interactions of the glenohumeral and scapulothoracic joints. Many practitioners believe that laxity testing of the shoulder is difficult, and they are unclear about its role in evaluation of patients. The objectives of the various laxity and instability tests differ, but the clinical signs of such tests can provide helpful information about joint stability. This article summarizes the principles of shoulder laxity testing, reviews techniques for measuring shoulder laxity, and evaluates the clinical usefulness of the shoulder laxity tests. Shoulder laxity evaluation can be a valuable element of the shoulder examination in patients with shoulder pain and instability.

Keywords: laxity testing; shoulder; review; physical examination

INTRODUCTION

With the increasing appreciation that all joints have a normal laxity pattern,^{7,31,67} the challenge for the clinician is to distinguish normal laxity from pathologic movements and instability of the joint. Matsen et al^{58(p786)} defined glenohumeral laxity as the ability of the humeral head to be passively translated on the glenoid fossa and glenohumeral instability as “a clinical condition in which unwanted translation of the head on the glenoid compromises the comfort and function of the shoulder.”

The shoulder is the most mobile joint in the body, and the shoulder's range of normal laxity values varies widely.^{31,51,53,88,89,96} Determining laxity of the glenohumeral joint is challenging because of the complexity of the combined motions of the glenohumeral and scapulothoracic articulations. Many clinicians believe that shoulder laxity is difficult to assess on physical examination.^{29,36,92,104}

Although recent biomechanical and clinical studies have helped to define normal shoulder laxity,^{31,51,53,84,88,89,96} clinicians can still have difficulty distinguishing normal from pathologic laxity, particularly in determining the direction or directions in which the patient's shoulder may be unstable. If

the clinician confuses normal laxity with instability and fails to identify the directions of instability, the method of treatment chosen (operative or nonoperative) and, potentially, the final result may be affected. In 1980, Neer and Foster⁷² described multidirectional instability (MDI) as instability in two or more directions, and they suggested that the hallmark of inferior instability was a positive sulcus sign. Their preliminary study described for the first time a heterogeneous group of patients who had ligamentous laxity, pain, and signs of instability. They noted that for the sulcus sign to be truly positive, it had to reproduce the patient's symptoms of instability. However, the results of the work of Neer and Foster are often misinterpreted, and subsequent reports have been inconsistent with regard to the criteria for inferior instability. One study has suggested that a positive sulcus sign should be based on the reproduction of symptoms of inferior instability and not on an arbitrary magnitude.⁶⁵ That study indicated that a sulcus sign determined to be positive based on magnitude alone might cause MDI to be overdiagnosed and might result in overtreatment of normal laxity patterns.⁶⁵

Likewise, laxity testing of the shoulder in an anterior-posterior direction has been recommended as a tool for determining nonoperative or operative treatment. The ability to sublaxate the shoulder over the glenoid rim anteriorly or posteriorly, with the patient awake or under anesthesia, has been interpreted by some authors to be a sign of instability.^{2,4,12,17,26,68,70,83} If the shoulder can be sublaxated over the glenoid rim anteriorly or posteriorly on laxity testing but does not reproduce symptoms of instability, the examiner should not interpret this as instability; the treatment chosen may be inappropriate.

[‡]Address correspondence to Edward G. McFarland, MD, c/o Elaine P. Henze, BJ, ELS, Medical Editor, Department of Orthopaedic Surgery, Johns Hopkins Bayview Medical Center, 4940 Eastern Ave., #A672, Baltimore, MD 21224-2780 (e-mail: ehENZE1@jhmi.edu).

No potential conflict of interest declared.

The distinction between laxity and instability is also important in overhead athletes, that is, those who reach or throw overhead. The clinician must use a history of pain and physical examination findings of a “loose” shoulder to determine whether the shoulder pain is caused by covert shoulder instability. Rowe and Zarins⁸⁵ were the first to suggest that a “dead arm” resulted from occult instability. Jobe et al⁴³ popularized this concept of occult instability as a source of pain in the overhead athlete. They noted that overhead athletes had substantial shoulder joint laxity, particularly in the anterior direction, which has been speculated to be the result of attenuation of the anteroinferior capsule secondary to repetitive forceful abduction, external rotation, and horizontal abduction. They associated this occult anterior instability with changes seen at the time of arthroscopy, including superior labral anterior posterior (SLAP) lesions and partial rotator cuff tears. Although such patients infrequently report that their shoulders subluxate or dislocate, they often complain that their shoulder feels “loose.”¹¹ This looseness has been assumed to represent some form of occult laxity, which Jobe et al⁴³ have suggested is anterior instability and others^{11,71} have suggested is a form of superior instability or superior “pseudolaxity.”

The objectives of this review are (1) to describe the biomechanical principles behind the concepts of laxity and instability and to summarize what is known biomechanically about normal shoulder laxity, (2) to address the techniques for measuring shoulder laxity and suggest methods for performing these examinations, and (3) to evaluate the role of laxity testing in assessing patients with shoulder instability or pain with potential instability.

BIOMECHANICS

Every joint has 6 degrees of freedom that are constrained to some degree in 1 or more directions (Figure 1). The glenohumeral joint is remarkable because it has so few restraints, yet maintains its stability. The restraints to movement of the humeral head on the glenoid include static and dynamic components. Static restraints involve the bony, labral, and ligamentous or capsular structures of the shoulder. The dynamic restraints involve the shoulder musculature and the “compression concavity” mechanism created by the rotator cuff.^{52,54}

Bone variables in the shoulder that affect shoulder stability include the humeral head, the glenoid, and the scapula. The shape of the scapula may contribute to stability because patients with glenoid dysplasia have a high rate of shoulder instability.^{93,98,105} Loss of glenoid bone from fracture or recurrent instability has been shown to affect shoulder stability.^{3,10,41,49,52,54,56,61} Approximately 20% of the surface of the glenoid can be removed before frank anterior instability of the glenohumeral joint occurs.⁴¹ Bony restraints to superior migration of the proximal humerus include the coracoid, acromion, and distal clavicle.⁶¹

Static soft tissue restraints to shoulder translation include the labrum, the capsule and capsular ligaments, and the rotator cuff tendons. The labrum provides stability by serving as an attachment for the glenohumeral ligaments and

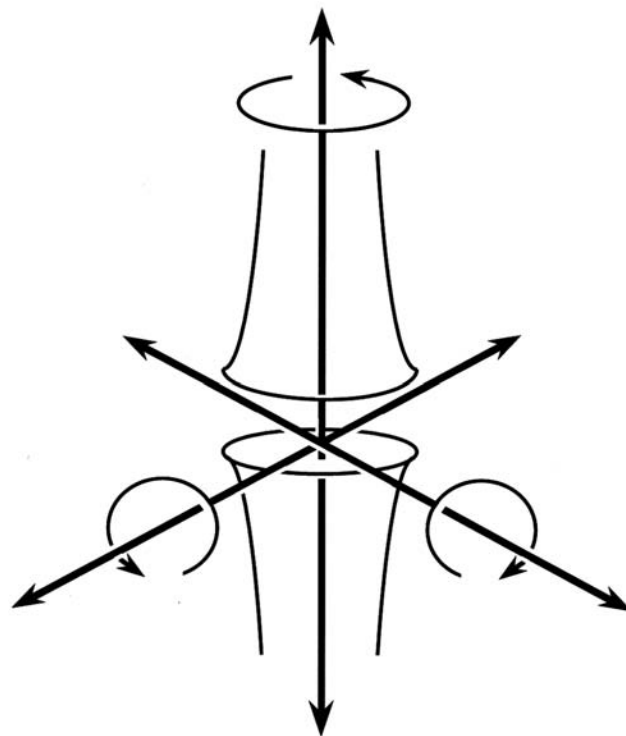


Figure 1. Schematic drawing of the 6 degrees of freedom of the humeral head on the glenoid. There are four primary directions of translation and two different directions of rotation. (Reproduced with permission from McFarland EG, Kim TK: Laxity and instability. In: *Examination of the Shoulder: A Complete Guide*. New York, NY: Thieme; 2006:167.)

by effectively deepening the glenoid by approximately 50%.^{19,39,52} The fibrocartilaginous ring also acts to resist forces by as much as 60%.⁵⁴

The capsule of the shoulder, which acts to restrain shoulder motion, includes the superior, middle, and inferior glenohumeral ligaments. These ligaments, which are important primary restraints for movement of the humerus on the glenoid, restrict different motions, depending on arm position, the degree of compressive force, and the amount of applied force to the ligament (Table 1). For any given position of the arm, the shoulder ligaments have a unique pattern of tension, relaxation, and stability.^{19,25,32,77,81,99,102} Some have suggested that these ligamentous restraints act in a circular fashion, so that translation in one direction will be restrained initially by the capsule on that side of the glenoid.^{19,81,103} As the translation increases, the capsule on the opposite side of the glenoid subsequently fails. This circle concept has been shown experimentally,^{6,79,94,95} but to our knowledge there are no randomized surgical series that prove that better surgical results are obtained with repair of both sides of the circle in shoulders with unidirectional instability patterns.

The rotator cuff tendons provide some static restraints to humeral head translation, but their main effect on shoulder joint stability is the generation of compressive forces by the

TABLE 1
Role of the Glenohumeral Ligaments in Shoulder Stability^a

Author(s)	SGHL	CHL	MGHL	IGHL
Basmajian and Bazant ⁵	Primary restraint to inferior translation in ADD	Primary restraint to inferior translation in ADD	N/R	N/R
Burkart and Debski ⁹	Restraint to inferior translation in 0° to 50° ABD	Restraint to inferior translation in 0° to 50° ADD	Restraint to anterior instability at 45° to 60° ABD	Primary restraint for anterior shoulder dislocation
Ferrari ²⁵	Restraint to ER <60° ABD	Restraint to inferior translation and ER	Restraint to ER at 60° and 90° ABD	N/R
Harryman et al ³²	Statistically significant restraint to posterior and inferior translation	Statistically significant restraint to posterior and inferior translation	N/R	N/R
Helmig et al ³⁸	Restraint in inferior translation	Primary restraint to inferior translation	N/R	N/R
O'Brien et al ⁷⁵	N/R	N/R	N/R	Restraint to anterior and posterior instability, primary stabilizer in ABD and ER
Ovesen and Nielsen ⁷⁷⁻⁸⁰	Restraint to posterior instability	Restraint to inferior instability; secondary role in posterior instability	Restraint to posterior instability	Posterior band restraint to posterior instability at 45° to 90° ABD
Turkel et al ⁹⁹	Minor role in anterior instability	N/R	Restraint to anterior instability at 45° ABD	Primary restraint to anterior instability at 90° ABD
Warner et al ¹⁰²	Primary restraint to inferior translation at 0° ABD and NL	No significant role for inferior translation when SGHL present	Restraint to inferior translation at 0° ABD and ER	Anterior band primary restraint to inferior translation at 45° ABD and NL; posterior band primary restraint to inferior translation at 90° ABD and NL

ABD, abduction; ADD, adduction; NL, neutral; ER, external rotation; SGHL, superior glenohumeral ligament; CHL, coracohumeral ligament; MGHL, middle glenohumeral ligament; IGHL, inferior glenohumeral ligament; N/R, not reported.

^aAdapted with permission from McFarland EG, Kim TK. Instability and laxity. In: *Examination of the Shoulder: A Complete Guide*. New York, NY: Thieme; 2006:162-212.

rotator cuff muscles. The increased contact pressure between the humeral head and the glenoid as a result of these compressive forces resists translational forces. This increased depth of the glenoid and the compressive forces that stabilize the humeral head has been called "concavity compression."^{52,54}

Shoulder laxity is also affected by the spatial relationship of the shoulder structures to each other in three dimensions. There is an increasing appreciation that glenohumeral joint stability may be influenced by the relationship of the scapula to the thorax.^{44-46,86} There are an enormous number of positions in which to evaluate shoulder laxity because of variations in the position of the humeral head on the glenoid and variations in scapular positioning on the thorax.

Another factor, seen primarily in in vitro studies rather than in clinical situations, is the negative intra-articular pressure generated by the articular fluid within a closed system; when the shoulder joint is vented in vitro by incising the capsule, there is more translation than in the unvented system.^{19,81,102}

Numerous biomechanical studies on the amount of translation of the humeral head on the glenoid have been conducted in cadavers (Table 2).^{84,87} Such studies are typically performed with the scapula fixed in some manner and the humeral head translated in different directions. Important variables in the methodology that affect the amount of translation shown in a study include whether the scapula was fixated or not, the position of the scapula relative to the humeral head if it was fixed solidly, how the centered position of the humeral head was established after each trial, how much compressive force was applied between the humeral head and the glenoid, whether that compressive force was applied via the cuff tendons or by the testing device, whether the rotator cuff tendons were intact, whether the joint was vented, how much force was used to translate the humeral head, what kind of sensors were used to determine the motion, the accuracy of the sensors, whether the sensors were attached to bone or to soft tissue, whether cyclical testing was performed, and how the endpoint of motion

TABLE 2
Shoulder Laxity: Biomechanical Studies

Authors	Cadaver Model ^a	Measurement Technique	Amount of Force (N)	Mean (Range) Anterior Laxity (mm)	Mean (Range) Posterior Laxity (mm)	Mean (Range) Inferior Laxity (mm)
Reis et al ⁸⁴	Shoulder specimen, scapula mounted	Spatial skin transducers	N/R	9.8 (3.7-14.7)	9.7 (3.8-17.2)	N/R
		Bone-pin sensors	N/R	10.1 (4.7-14.6)	11.5 (2.9-20.0)	N/R
Sauers et al ⁸⁷	Shoulder specimen, scapula mounted	Spatial skin transducers	200	11.8 (3.7-26.9)	8.6 (0.5-18.5)	20.2 (8.4-31.3)
		Bone-pin sensors	200	10.3 (3.9-19.6)	9.0 (2.3-22.3)	15.5 (4.0-28.4)

N/R, not reported.

^aIntact (not vented) shoulder.

was determined. These variables explain the differences in the results in the studies summarized in Table 2.

Some in vivo human studies of translation of the humeral head on the glenoid have used pins implanted into the bones of the shoulders.^{31,53,84,87,97} Electromagnetic sensors were then attached to the humerus and scapula, and tracked as they moved, providing an accurate measure of the bone movements (including translations) in relation to each other.^{31,69,84} Harryman et al³¹ studied normal volunteers with electromagnetic devices attached to pins and found that in asymptomatic subjects, translation averaged 7.8 ± 4.0 mm anteriorly and 7.9 ± 5.6 mm posteriorly. However, the variables that affect such results are very similar to those listed above for cadaveric studies.

To avoid the morbidity of pins placed in the scapula or humerus in in vivo human subjects, attempts have been made to use electromagnetic tracking sensors placed on the skin over the shoulder's bony landmarks (Table 3). Sauers et al⁸⁷ and Reis et al⁸⁴ have compared laxity measures with sensors applied to the skin and directly bone-pinned and found that noninvasive surface measures are reasonably valid. The variables that affect such studies include the position of the subject (seated or supine), whether the scapula was stabilized, whether sensors used for measuring the translation were attached to the skin or to pins placed into the shoulder bones, how much force was applied to the shoulder, whether the subjects had warmed up before testing, and whether the subjects were relaxed.

Because there are so many possible variations in the experimental design, the amount of translation seen in biomechanical studies using electromagnetic sensors attached to the skin is likewise highly variable.^{84,87,89} The salient findings were that anterior translation varied from to 3.7 to 26.9 mm, and posterior translation from 0.5 to 18.5 mm.⁸⁷

Similar technology has been used to evaluate inferior translation of the humeral head on the glenoid. Although it has been suggested by some authors that a higher sulcus sign in external rotation than in internal rotation is an indication of a rotator cuff lesion that requires repair, there is little evidence to support that conclusion.^{15,16,73,102} Warner

et al¹⁰² found that in cadavers, the structure most responsible for restricting inferior translation with the arm at the side was the superior glenohumeral ligament.

Some amount of translation of the humeral head on the glenoid is an obligate physiologic motion required for normal range of motion. Obligate humeral head translations have been recorded with shoulder motion but not during laxity testing.³⁰ Small magnitudes of humeral head translation are normal and have been recorded with active¹⁰⁶ and passive³⁰ humeral elevation. This obligate translation of the humeral head on the glenoid is physiologic and, in fact, necessary to achieve the large degrees of freedom afforded the highly mobile shoulder. However, distinguishing normal translations of the shoulder from abnormal ones continues to be an important consideration for the clinician who examines the shoulder and treats its disorders.

MEASURING SHOULDER LAXITY

Because sophisticated biomechanical techniques for measuring shoulder translations are not available in clinical practice, other methods of measurement have been explored. Because the clinical evaluation of shoulder translation can be difficult to perform, attempts to measure shoulder laxity have incorporated stress radiographs, ultrasound, and instrumented devices. Although the use of these techniques requires further validation, these studies have provided important information about the factors influencing shoulder translations.^{18,21,28,31,37,42,47,59,74,82,90}

Stress Radiographs and Ultrasound

Stress radiographs have been used in an attempt to standardize laxity testing and potentially diagnose instability with a numeric value (Table 4).^{31,37,59,74,82,90} Hawkins et al³⁷ used fluoroscopy to measure humeral head translation in anesthetized normal patients and those with shoulder instability. They found a wide range of shoulder translation. Normal patients (ie, asymptomatic patients without shoulder

TABLE 3
In Vivo Human Laxity: Biomechanical Studies

Authors	Measurement Technique	Force Application Technique	Amount of Force (N)	Mean (Range) Anterior Laxity (mm)	Mean (Range) Posterior Laxity (mm)	Mean (Range) Inferior Laxity (mm)
Borsa et al ⁸	Spatial skin transducers	Measured force applicator	203, 192, 181	14.5 (10.1-18.7)	14.0 (7.7-19.3)	13.9 (8.9-23.1)
Harryman et al ³¹	Bone-pin sensors	Manual	N/R	7.8 (2.2-13.2)	7.9 (2.8-18.9)	10.6 (5.0-13.1)
Lippitt et al ⁵³	Bone-pin sensors	Manual	N/R	8.1 (~2.6-14.0)	7.4 (~3-19.2)	11.2 (~5.5-15)
Sauers et al ⁸⁸	Spatial skin transducers	Measured force applicator	67, 89, 111, 134	10 (4.3-19.4)	10.3 (3.3-19.7)	N/R
Sauers et al ⁸⁹	Spatial skin transducers	Measured force applicator	67, 89, 111, 134	9.5 (4.3-17.3)	11.1 (4.7-17.5)	N/R

N/R, not reported.

TABLE 4
Estimated Translations (Percentage of Humeral Head Movement)

Author(s)	Normal Anterior Humeral Head Translation (%)	Normal Posterior Humeral Head Translation (%)
Harryman et al ³¹	<35	<35-39
Hawkins et al ³⁷	<17	<26
Maki ⁵⁹	<25	<50
Norris ⁷⁴	None	<50
Papilion and Shall ⁸²	<14	<37
Schwartz et al ⁹⁰	<50	<50

instability) exhibited on average 17% anterior, 26% posterior, and 29% inferior humeral head translation. However, they also found that patients with anterior instability and multidirectional instability exhibited similar and overlapping values, making it difficult to diagnose instability based on radiographic translation values alone. Georgousis and Ring²⁸ used a shoulder positioning device to document laxity radiographically, and Ellenbecker et al²¹ used that technique to assess anterior laxity in baseball pitchers.

Ultrasound also has been used to assess shoulder laxity.^{18,42,47} Borsa et al⁷ used ultrasound and stress radiography to compare anterior and posterior glenohumeral translation. They reported an overall correlation coefficient of 0.79 between ultrasound and stress radiography. For anterior translation, the intratester reliability was 0.72 and the intertester reliability was 0.96. For posterior translation, the intratester reliability was 0.85 and the intertester reliability was 0.99. They concluded that ultrasound was comparable to stress radiography in accuracy, and that ultrasound offered other advantages such as no radiation and the ability to assess the status of the rotator cuff.

In current clinical practice, however, the use of stress radiographs and ultrasound are limited by several factors. First, there are no absolute values of translation of the humeral

head on the glenoid that definitively confirm a diagnosis of instability.^{31,37,53,96} Even if stress radiography shows that the humeral head subluxates over the glenoid rim, this finding does not confirm that the glenohumeral joint is unstable.^{22,51,63} Similarly, neither of these techniques has been found to correlate with grading scales commonly used in clinical practice for measuring translations.^{33,48,63} Another difficulty with ultrasound and stress radiography is that they are technically demanding. Stress radiography can be challenging because it requires axillary view radiographs, which must be obtained at the same angle with every assessment to provide meaningful measurements. Similarly, ultrasound requires technical expertise and training that can vary from examiner to examiner. Finally, currently there is no means of controlling the amount of force applied to the shoulder when measuring translations under stress radiography or ultrasound, thus comparison of one study to another may not be possible. Additional research is needed before stress radiography or ultrasound can be recommended as an office tool for evaluating glenohumeral instability.

Instrumented Devices

Another technique for measuring glenohumeral translations involves the use of instrumented devices. These devices are similar in concept to the KT-1000 arthrometer (MEDmetric Corp, San Diego, Calif) used to measure translation in the knee. Studies with these devices have shown a wide variation of laxity in the shoulder (Tables 2 and 3).^{84,88,89} However, the devices are limited by changes in translation secondary to soft tissue compliance and by the patient's inability to relax. Furthermore, although there have been attempts to measure humeral head translations with these devices and to correlate them with instability, the conclusion of several studies is that no single distance of translation can be used as a standard to make the diagnosis of instability.^{31,53,96} Additional research on instrumented devices for measuring glenohumeral translation is needed before their precise role in the evaluation of patients with possible instability of the shoulder can be defined.

Clinical Techniques

The most common method for measuring shoulder translations has been the examination of the shoulder by the clinician or practitioner in the office or with the patient under anesthesia. In the office, laxity testing can be performed with the patient in an upright or supine position. However, to be effective, laxity testing in the office requires the patient to be relaxed enough to allow translation of the humeral head on the glenoid. We agree with Gerber and Ganz²⁹ and Emery and Mullaji²² that humeral head translation is better appreciated with the patient in a supine position because the patient seems to be more relaxed than when sitting. Determining the quality of the end point as “soft” or “firm,” as is done in the knee and other joints, is not practical in the shoulder when measuring laxity.

Anterior and Posterior Drawer Tests

The anterior and posterior drawer tests were described initially by Gerber and Ganz in 1984.²⁹ The anterior drawer test is performed with the patient supine and the examiner standing to the side (Figure 2). The examiner holds the patient's arm in 80° to 120° of abduction, 0° to 20° of forward flexion, and 0° to 30° of external rotation. The examiner holds the hand of the extremity being evaluated in the examiner's axilla. One of the examiner's hands is placed on the humeral shaft to provide an anteriorly or posteriorly directed force. The other hand is used to stabilize the scapula by placing the fingers posteriorly along the scapular spine and the thumb anteriorly on the coracoid.

The anterior drawer test may be difficult to perform because of the challenge of controlling the rotation of the scapula. Another method for performing the anterior drawer test has been reported to help control the rotation of the scapula (Figure 3).⁶⁷ To examine a left shoulder, we recommend that the examiner use his or her left hand to hold the patient's left wrist hand and his or her right hand to hold the patient's upper arm. The patient's shoulder is abducted 60° to 70° and slightly internally rotated while a slight axial load is applied to the glenohumeral joint. This axial load controls the scapula but also improves the examiner's ability to feel the humeral head subluxate over the glenoid rim.⁹¹ The examiner then applies an anterior force and translates the humeral head onto the chest in one motion. It is important to translate the whole arm and not just the humeral head; the latter would push the head anteriorly and selectively tighten the anterior structures, preventing subluxation.

The posterior drawer test (Figure 4) also is performed with the patient supine, but there are subtle differences from the anterior drawer test.²⁹ If the left shoulder is being examined, the examiner holds the patient's proximal forearm and flexes the elbow to 120° while the shoulder is placed in 80° to 120° of abduction and 20° to 30° of forward flexion. The scapular spine is held with the examiner's right index and middle fingers. The examiner's thumb is placed lateral to the coracoid, where “its ulnar aspect remains in contact with the coracoid while performing the test.”^{29(p554)} Using the left hand, the examiner then flexes the patient's

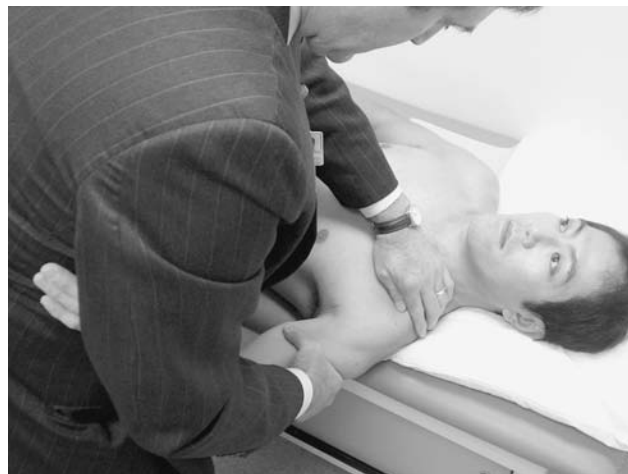


Figure 2. Technique for performing an anterior drawer test as described by Gerber and Ganz.²⁹

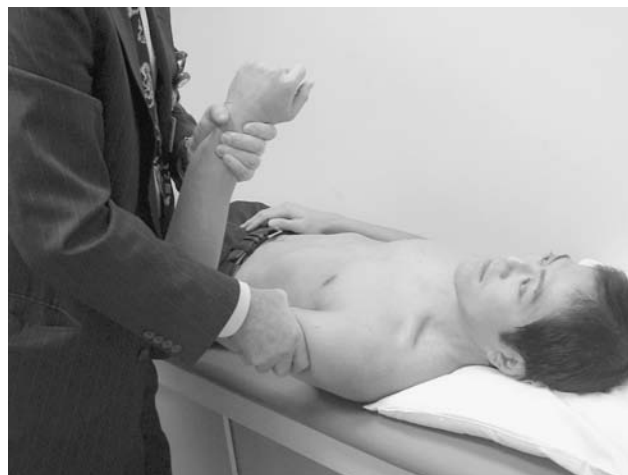

Figure 3. Modified technique for performing the anterior drawer test to control scapular rotation.

arm 60° to 80° while slightly internally rotating the arm. Simultaneously, the examiner's thumb exerts a posterior pressure to translate the head. The fingers along the scapular spine can palpate the head as it translates posteriorly. The posterior pressure on the humeral head is then relieved, to see if the head will lock out.

The posterior drawer test can be modified to promote patient relaxation and increased translation. The arm is placed in 50° to 60° of abduction and in neutral rotation (Figure 5). In this “unpacked” position, the posterior capsule displays the most laxity.^{20,40,57} The examiner's hand is placed with the thumb on the anterior humeral head and the remaining fingers behind the humeral head. As the thumb pushes the humeral head posteriorly, the arm is flexed forward toward the examiner. The fingers placed posteriorly

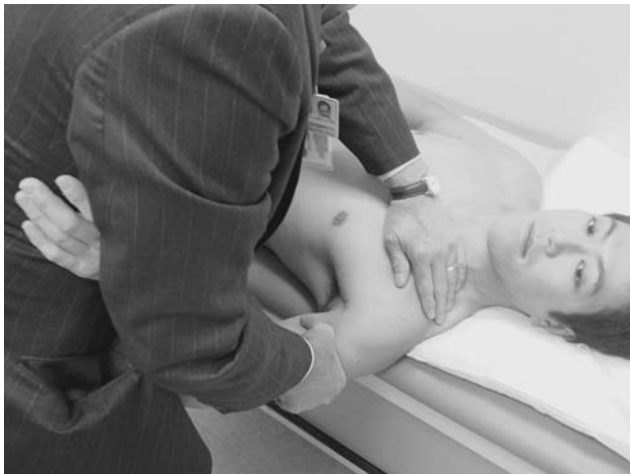


Figure 4. Technique for performing a posterior drawer test as described by Gerber and Ganz.²⁹

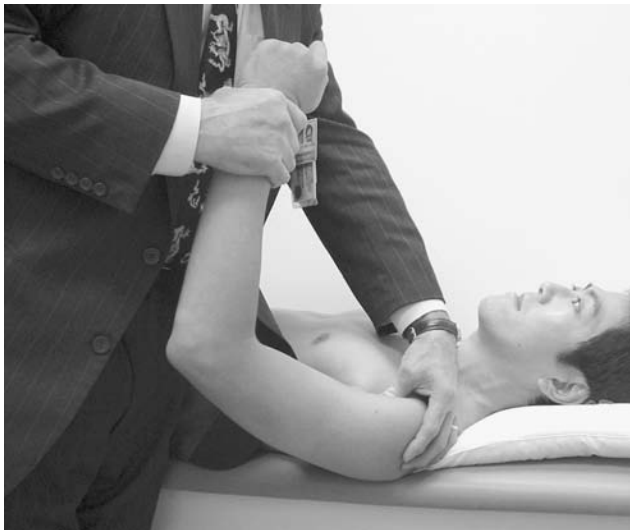

Figure 5. Modified posterior drawer test, which is performed at less abduction than that described for a standard posterior drawer test.

can be used to feel the humeral head subluxate over the posterior glenoid rim. To reduce the humeral head, the arm is extended back toward the table and the reduction of the humeral head into the joint can be palpated. If the examiner's thumb on the proximal humerus causes pain during testing, the examiner can use the palm of the hand to push the proximal humerus posteriorly.

The validity of the anterior and posterior drawer tests has not been established with biomechanical testing. In other words, although cadaveric studies have shown that there are large variations in shoulder laxity both anteriorly and posteriorly, no study has determined that a certain degree of translation is abnormal. As a result, with the anterior and posterior drawer tests, there is no specific degree of translation that will absolutely make the diagnosis of shoulder instability.

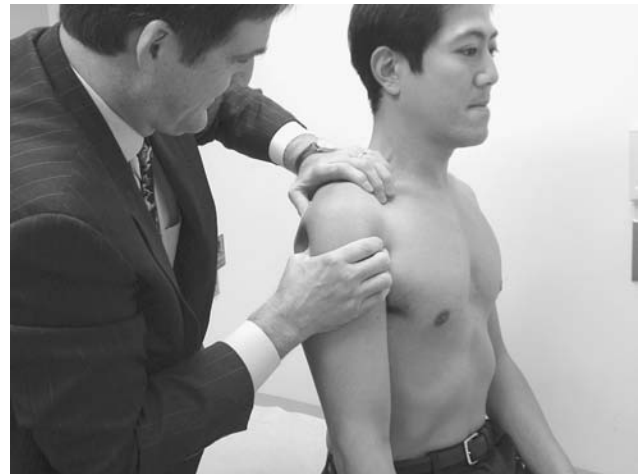

Figure 6. Technique for performing a load and shift test with the patient seated.

Load and Shift Test

The load and shift test, originally described by Silliman and Hawkins,⁹¹ is an alternative modality for measuring anterior and posterior laxity. It is performed with the patient in the upright or supine position. The arm is placed in 20° of abduction, 20° of forward flexion, and in neutral rotation.⁹¹ With the patient in the upright position, the examiner stands behind the patient's arm to be tested (Figure 6). The examiner stabilizes the scapula with one hand and grasps the proximal arm near the joint with the other hand. A slight axial load is then applied between the humeral head and glenoid, which facilitates the ability to feel the humeral head slide over the rim.⁹¹ As the head is loaded, anterior and posterior forces are applied to assess the translation of the humeral head on the glenoid.

The load and shift test can be performed with the patient supine, using the same arm positions. Tzannes and Murrell¹⁰⁰ and Tzannes et al¹⁰¹ have described a variation of the load and shift test in which the examiner sits on a stool next to the patient (Figure 7). The patient's arm is placed on the examiner's thigh, which facilitates patient relaxation. The examiner's hands are placed as described above, and the translations are performed. Matsen et al⁶⁰ have described a similar technique (termed a "push-pull" test) to evaluate posterior translation of the humeral head. With the patient supine and the shoulder in 90° of abduction and 30° of flexion, the examiner pulls up on the wrist with one hand while pushing down on the proximal humerus with the other hand.⁶⁰

Sulcus Sign

The sulcus sign was described first by Neer and Foster,⁷² who used the test as a measure of inferior laxity. They suggested that a large sulcus sign on examination or with stress radiography indicated inferior instability if it reproduced the patient's symptoms of pain or instability. The test can be performed with the patient standing, sitting, or supine. The test

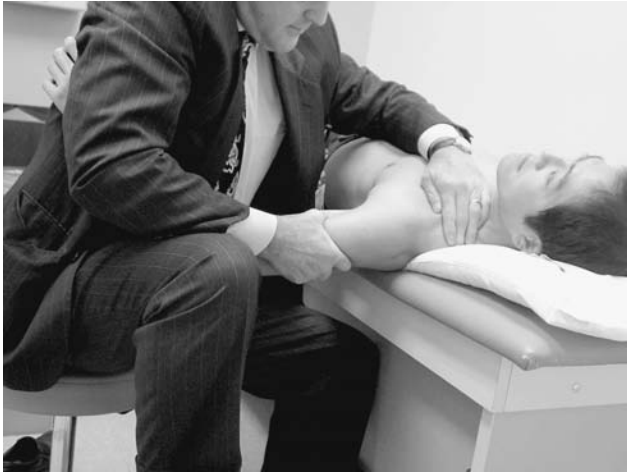

Figure 7. Technique for performing the load and shift test with the patient supine. To promote relaxation of the patient, the arm can be placed on the thigh of the examiner as described Tzannes and Murrell¹⁰⁰ and Tzannes et al.¹⁰¹

can be performed on one or both extremities simultaneously. Another variation is to test one extremity but to place one hand on the shoulder to stabilize the scapula. An inferior distraction then is applied to the arm in an inferior direction.

In our experience, more inferior translation can be obtained if the patient is sitting relaxed with both hands resting in the lap than in the standing or supine position. In the seated position, both arms simultaneously are pulled inferiorly so that the amount of translation in each shoulder can be compared (Figure 8). The test is then repeated one arm at a time, with the arm externally rotated to its maximum to test the superior glenohumeral ligament and rotator cuff interval.^{25,32,102} In the sulcus sign test, the magnitude of translation has been graded in most studies as grade I (<1 cm translation), grade II (1 to 2.0 cm), or grade III (>2.0 cm).^{1,37,91} For sulcus testing, the patient should be asked if the testing reproduces the symptoms of instability.

Gagey Hyperabduction Test

This test was described in 2001 by Gagey and Gagey²⁷ for assessment of the laxity of the inferior glenohumeral complex. The test is performed with the examiner standing behind the seated patient, with one forearm pressing down firmly to stabilize the patient's scapula, while the patient's arm is abducted until the scapula is felt to be moving (Figure 9). The amount of abduction is measured when glenohumeral motion has stopped and the scapula begins to move. This movement, where glenohumeral motion ends and scapulothoracic motion begins, was termed range of passive motion of the shoulder in abduction (RPA). According to the study by Gagey and Gagey,²⁷ the RPA should be less than 105° of abduction, and the test was considered positive for laxity of the inferior glenohumeral ligament if the RPA was more than 105°.²⁷

To our knowledge, the Gagey hyperabduction test has been evaluated for reliability only by its developers. Gagey and

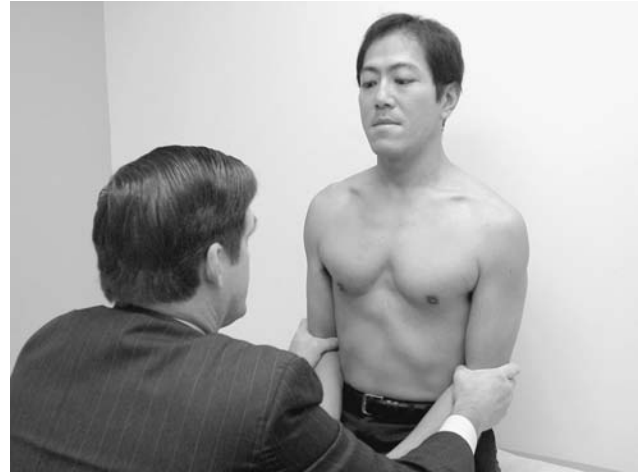

Figure 8. The sulcus sign can be performed with the patient sitting, with both arms relaxed in the lap.

Gagey²⁷ first studied 100 cadavers in which the shoulder muscles had been removed but the glenohumeral ligaments remained intact. They found that the average abduction was 83.5° with the capsule intact, 96.5° with sectioning of the anterior band of the inferior glenohumeral ligament complex, and 95.5° with sectioning of the posterior band. Their study assumed that no soft tissue other than the inferior glenohumeral ligament complex affects abduction.²⁷ Then they collected normative data for 100 volunteers (normal RPA averaged 89°) and determined that the interobserver reliability of the test was excellent (ICC = 0.87 to 0.90) and that the intraobserver reliability was 0.84 to 0.89.²⁷

Testing Under Anesthesia

Under anesthesia, the degree of laxity of the shoulder as determined by these examination techniques generally increases.^{23,107} Faber et al²³ found that, in general, laxity testing under anesthesia increases shoulder laxity by half a grade, although no current system of laxity testing allows for the laxity grading system to be subdivided into fractions. Similarly, Yoldas et al¹⁰⁷ found that, compared with the preoperative examination, posterior and inferior laxity can be increased under anesthesia.

Coffield and Irving¹³ recommended a systematic laxity examination under anesthesia to help diagnose shoulder instability. They described the assessment of laxity in multiple directions with the arm in varying degrees of rotation and elevation and suggested that this system could detect abnormal laxity that might not be detected in the awake patient. Coffield et al¹⁴ reported that diagnosing shoulder instability with an examination under anesthesia had a sensitivity of 100%, a specificity of 93%, a positive predictive value of 93%, and a 7.4% false-positive rate. They used operative findings such as a Bankart lesion or excessive laxity of the capsule to diagnose instability. More recently, Oliashirazi et al⁷⁶ defined anterior shoulder instability with

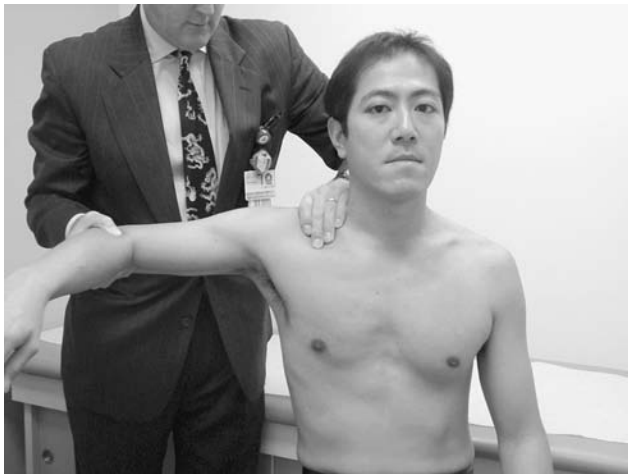

Figure 9. The Gagey test, in which the examiner stabilizes the scapula with one hand and elevates the arm with the other until an end point is felt.

Cofield's technique as grade-III translation or higher, or translation two grades higher than that of the contralateral shoulder. They also reported a sensitivity of 83% and a specificity of 100% for an examination under anesthesia to diagnose anterior shoulder instability. However, their technique assumed that asymmetry between shoulders is inherently abnormal, whereas other studies have shown that asymmetry of shoulder translations is not necessarily a valid criterion for making the diagnosis of instability.^{51,63}

Quantifying Translations Obtained With the Clinical Examination

Quantifying the amount of translation during laxity testing in the shoulder is important in communicating with other health care professionals and guiding treatment. Three measures for quantifying translations of the humeral head on the glenoid have been reported (Figure 10).^{35,37}

Humeral Head Movement. The first technique is to estimate in millimeters the distance the humeral head moves. Four grades of anterior and posterior translation of the humeral head have been suggested: grade 0, no or minimal translation; grade I, 0 to 1 cm of translation; grade II, 1 to 2 cm of translation or translation to the glenoid rim; and grade III, >2 cm of translation or translation over the rim.³⁷ A similar grading system is used for inferior laxity testing.^{1,37,91} These numbers represent estimates on the part of the examiner. To our knowledge, there are no studies that validate these measures or establish interobserver or intraobserver reliability of this measurement system.

These classifications have not been validated in biomechanical or clinical studies, but the reliability of this schema for inferior laxity has been the subject of several studies. Levy et al⁵⁰ studied the sulcus sign in 43 college athletes who had no symptoms of shoulder instability and no previous shoulder problems. Agreement among the four examiners on the degree of sulcus sign ranged from 39% to 64%,

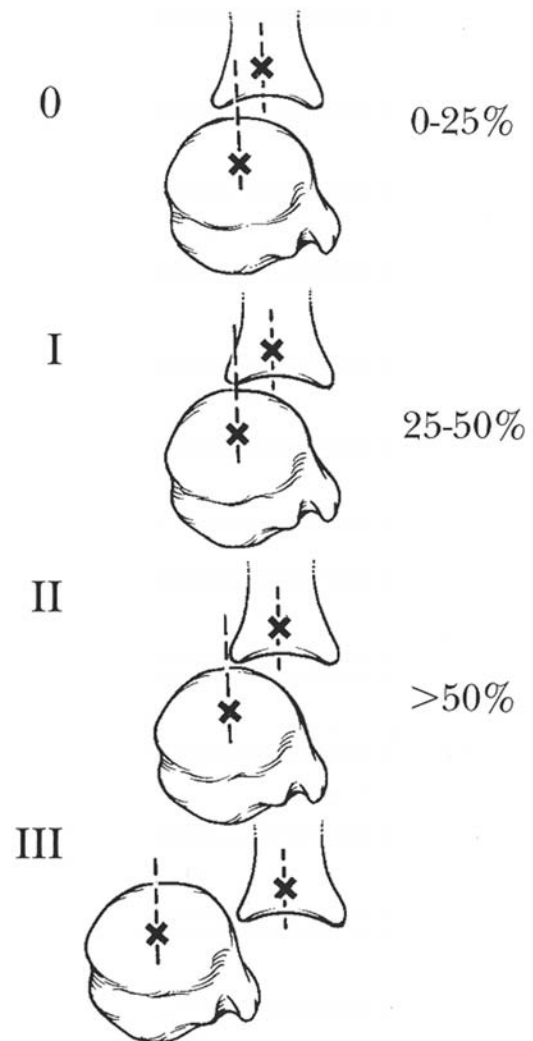


Figure 10. Humeral translations can be measured in millimeters, in percentage head diameters, or by what the examiner feels when the humeral head subluxates over the rim of the glenoid. (Reproduced with permission from McFarland EG, Kim TK: Laxity and instability. In: *Examination of the Shoulder: A Complete Guide*. New York, NY: Thieme; 2006:179.)

with a kappa value <0.5 (fair to poor). For inferior translations using the sulcus sign test, when grades 0 and I were equalized or considered one group, agreement among the examiners was 77% to 93%, with a kappa value >0.5.

A similar study was performed to determine interobserver agreement for the sulcus sign on 88 shoulders by an attending physician and sports medicine fellows.⁶² Agreement between the attending surgeon and fellows was 70% (range, 61% to 87%), with a kappa value of 0.38.⁶² Grade I had the highest level of agreement (80%). The higher the grade of the sulcus sign, the lower was the agreement between observers (grade-II agreement, 65%; grade-III agreement, 0%).⁶²

Percentage of Humeral Head Diameter. The second measure for humeral head translations is a percentage of

humeral head diameter.^{17,35} Normal translation has been defined differently by different researchers, and reported estimates for anterior translations vary from 0% to 50% of the humeral head diameter and 26% to 50% of the humeral head diameter for posterior translations (Table 4). Similarly, a wide variety of humeral head diameters have been suggested to represent instability.^{31,37,59,74,82,90}

There are several problems with this measure for translations of the humeral head. First, the wide variety of humeral head sizes and shapes cannot be assessed accurately without radiographs or some other measure. Second, Harryman et al³¹ suggested that using humeral head diameters as a measure of translation was not valid. They estimated a humeral head size of 47.3 mm in anterior-posterior diameter and 49.8 mm vertical height from previously obtained data and then computed the percentage of head diameter translation in subjects who had pins in their shoulder bones and attached electromagnetic spatial sensors. They found that the average translations obtained were 35% of the humeral head diameter anteriorly, 35% to 39% posteriorly, and 44% inferiorly.³¹ To our knowledge, no study has validated the use of the percentage of humeral head diameter as an accurate and reliable measure of humeral head translations.

Degree of Humeral Head Subluxation. A third way to quantify humeral head translation is to report what is felt and seen by the examiner when the shoulder is translated. In the schema proposed by Hawkins and Bokor³⁴ in 1990, the translation grades were: grade 0, normal motion; grade I, translation of the head to the rim; grade II, translation of the head over the rim; and grade III, translation was "lock out" (the humeral head remains out of the joint when the examiner's hands are removed). The advantage of this measuring system is that it reports what the examiner feels and does not represent absolute distance of translation of the humeral head. Because it is difficult to distinguish normal translation (grade 0) from translation of the humeral head to the rim (grade I), this schema has been modified to only three grades: grade I, not over the rim; grade II, over the rim; and grade III, lock out.^{51,63}

The reliability of this classification scheme for anterior and posterior translations has been the subject of several studies. Using the grading system of Hawkins and Bokor,³⁴ Levy et al⁵⁰ studied the interobserver reliability of the laxity examination and the drawer tests in 43 athletes. The examinations were performed by two sports medicine fellows, a senior resident, and an experienced attending physician. The authors found an average interobserver agreement between the attending and the other observers of 43% to 45% for anterior translations and 44% to 52% for posterior translations; the average value for all observations was 47%.⁵⁰ They also found that if grades 0 and I were consolidated using a modified Hawkins scale, the agreement increased to 65% to 67% for anterior translation and 59% to 75% for posterior translations; for all observations, it was 73%.⁵⁰

A similar study of interobserver reliability showed increased agreement if a modified Hawkins scale was used.⁶² Four fellows examined patients under anesthesia with a modified anterior and posterior drawer test, and the

results were compared with those obtained by an experienced attending examiner. The authors found that agreement on anterior translation averaged 78% (range, 69% to 89%), and agreement on posterior translation averaged 70% (range, 57% to 87%). That study, and the one by Levy et al,⁵⁰ suggest that combining grade-0 and grade-I translations increase interobserver agreement regarding the degree of shoulder translation.⁶²

Levy et al⁵⁰ also studied the intraobserver reliability of the modified Hawkins grading system. They found that intraobserver agreement with a Hawkins scale averaged 46%, but agreement with a modified Hawkins scale averaged 73%. A similar study of 28 shoulders by one experienced examiner suggested an intraobserver reproducibility of 100% for anterior translations and 86% for posterior translations using a modified Hawkins scale.⁶⁵

These studies indicate that interobserver and intraobserver reliability is moderate when using a modified Hawkins scale for grading anterior and posterior shoulder laxity and that examiner experience can be a factor when performing these maneuvers. Accordingly, when analyzing the results of published studies using such measures, it is important to note whether the examination performed was a load and shift test or a drawer test and to consider the number and experience of the examiners.

ROLE OF LAXITY TESTING IN CLINICAL PRACTICE

Clinical studies of shoulder laxity have shown that (1) the range of shoulder laxity in normal subjects varies widely and the ability to sublaxate the shoulder over the glenoid rim is essentially a normal variant^{31,51,53,63,64,88,89,96}; (2) asymmetry of shoulder translations may not necessarily indicate that the shoulder joint is unstable^{21,51}; and (3) although inferior laxity is a common finding, the definition of "abnormal" inferior translation remains controversial.

Studies of the distribution of normal shoulder laxity have shown that the ability to sublaxate the shoulder over the glenoid rim in asymptomatic shoulders is essentially a normal variant.^{51,64} Emery and Mullaji²² were the first to show in children that substantial anterior, posterior, and inferior laxity was common and normal. In such asymptomatic subjects with no previous shoulder problems, they found, based on laxity testing, "signs of instability" in 57% (56 of 98) of the boys' shoulders and in 48% (25 of 52) of the girls' shoulders. They found a positive posterior drawer test to be the most common finding (63 of 150 shoulders, or 42%) and that 17 of 150 shoulders (11%) of these asymptomatic school children had signs of multidirectional instability, which was defined as a positive sulcus sign with a positive anterior or posterior drawer test.²²

Another study assessed 178 athletes with no previous shoulder problems who underwent a modified posterior drawer and sulcus testing during the preseason physical examinations.⁶³ The authors found that the shoulders of 51% (125 of 246 shoulders) of the male athletes and 65% (71 of 110 shoulders) of the female athletes could be sublaxated over the posterior glenoid rim, and that 3% (4 of

123 athletes) of the men and 9% (5 of 55 athletes) of the women had a grade-III sulcus sign.

Lintner et al⁵¹ studied the distribution of shoulder laxity in 76 Division-I athletes with asymptomatic shoulders who had no previous shoulder problems or surgeries and found that grade-II translation was essentially a normal variant. Of the 152 shoulders, 21% (31 of 152) could be subluxated over the rim anteriorly or were grade II, 54% (83 of 152) could be translated over the rim posteriorly, and 6% (9 of 152) had a grade-II sulcus sign.

With the use of anterior and posterior drawer tests, asymmetry of shoulder laxity has been shown to be a common finding that may not necessarily indicate an unstable shoulder. Lintner et al⁵¹ found that 32% (24 of 76) of the Division-I athletes in their study had at least one grade or more of translational asymmetry and that 79% (19 of 24) of the athletes with asymmetrical shoulders had greater laxity in the nondominant shoulder. McFarland et al⁶³ found that 10% (2 of 178) of high school and collegiate athletes undergoing preseason physicals possessed asymmetrical posterior laxity. Ellenbecker et al²¹ found that 30% (6 of 20 athletes) of professional baseball pitchers had asymmetry of one grade or more with anterior laxity testing and that 83% (5 of 6 athletes) of the pitchers with asymmetry had greater translation in the dominant extremity.

Studies of the examination of shoulder translations in patients under anesthesia demonstrate that it is quite common for normal shoulders to be capable of being subluxated over the glenoid rim. A study by McFarland et al⁶⁴ of patients with a variety of diagnoses using a modified anterior and posterior drawer found that overall 84% (76 of 90) of patients could be subluxated over the anterior rim (a Hawkins grade II or III) and that 75% (68 of 90) could be subluxated over the posterior rim. Using the same cohort, the ability to subluxate the shoulder over the rim was demonstrated to decrease with age; however, this cohort included only patients undergoing surgery.⁶⁶

Inferior laxity of the shoulder in clinical practice has been studied less frequently than anterior and posterior translations. In a study of asymptomatic collegiate athletes, Lintner et al⁵¹ found 69% (105 of 152) of the shoulders had a grade-I sulcus sign, whereas 6% (9 of 152) possessed a grade-II sulcus sign. A study of asymptomatic adolescent athletes⁶³ demonstrated that if a positive sulcus sign was a grade II or III, then 54% (66 of 123) of males and 64% (35 of 55) of females had positive sulcus signs. Emery and Mullaji²² reported a positive sulcus sign in 11% (17 of 150) of asymptomatic school children. We conclude that a positive asymptomatic sulcus sign is a normal laxity variant.

We found only one study evaluating the use of the RPA for inferior shoulder laxity. Gagey and Gagey²⁷ used this examination on 90 patients with instability; 60 had "recurrent dislocations," and 30 had had "transient instability." In 85% of patients, the RPA in the affected side was $>105^\circ$ and that in the unaffected side was a maximum of 90° . These values did not change with anesthesia. These patients underwent surgery, and the investigators found that all patients with an elevated RPA had some form of labral disruption. The authors concluded that the RPA was a valid measure of inferior glenohumeral ligament laxity.²⁷

Its role in laxity testing is currently not well known, and further studies are warranted to confirm its clinical utility.

ROLE OF LAXITY TESTING IN EVALUATING INSTABILITY AND PAIN WITH POSSIBLE INSTABILITY

Although the absolute translations of the humeral head on the glenoid do not provide sufficient information to confirm reliably a diagnosis of instability, laxity tests that reproduce symptoms of instability may have some utility in the examination of the patient for whom the diagnosis is uncertain. In this instance, the laxity evaluation reproduces the symptoms of subluxation that the patient feels when the humeral head is subluxated over the glenoid rim. Often, the patient will exclaim "that's what my shoulder is doing, only worse." If laxity testing does not reproduce the symptoms experienced by the patient, that finding does not rule out the possibility of other occult instability patterns.

There have been few studies evaluating the usefulness of laxity testing that reproduces the patient's instability symptoms. One recent study of the posterior drawer test in patients with posterior instability found that laxity testing that produced a symptomatic grade-II or grade-III subluxation was 42% sensitive and 92% specific for making the diagnosis of instability.⁶²

In another study, patients with traumatic, anterior instability were examined with an anterior drawer test, and the investigators found that only 87% of the patients would relax enough in the office to allow the examination to be performed.²⁴ In patients with arthroscopically confirmed diagnosis of traumatic anterior shoulder instability, those investigators found that, if anterior drawer testing of the subluxation of their shoulders (a grade-II or grade-III translation) reproduced their symptoms of instability, the anterior drawer test had a sensitivity of 53% and a specificity of 85% for anterior instability.

Use of the drawer tests as a provocative test has several limitations: (1) the patient must be relaxed for the test; (2) the patient often has to be queried as to whether a subluxation reproduces their symptoms; and (3) its role in detecting other instability patterns, such as instability in multiple directions, has not been established if subluxation reproduces the patient's symptoms of instability.

Several studies have shown that the production of pain upon laxity testing does not confirm a diagnosis of shoulder instability. Speer et al⁹⁴ reported an overall accuracy of $<50\%$ when pain was a positive test with relocation testing, a value that increased to $>80\%$ if apprehension was used as a positive test. They found reproduction of pain with apprehension testing or diminution of pain with relocation testing to be a common finding in other diagnoses. Apprehension was highly specific for the instability patients.⁹⁴ Lo et al⁵⁵ demonstrated the relocation test to be more predictive of anterior shoulder stability when reproduction of apprehension and relief of apprehension was used as a positive test versus reproduction and relief of pain. The specificity and positive predictive values for the relocation test were both 100% when apprehension was used as a positive test, but

those values decreased to 43% and 15%, respectively, when pain was used as a positive test.⁵⁵ Similarly, Farber et al²⁴ found diagnostic value with the apprehension, relocation, and anterior drawer tests in diagnosing anterior shoulder instability when apprehension was used as a positive result. The apprehension and relocation tests produced a likelihood ratio of 20.2 and 10.4, respectively, but decreased to 1.1 and 3.0, respectively, when pain was used as a positive test. Pain production with anterior drawer testing could not confirm a diagnosis of anterior shoulder instability from other diagnoses. Low sensitivity, specificity, and likelihood ratios have been reported for diagnosing posterior instability when pain was reproduced with posterior apprehension and posterior drawer testing.⁶²

To our knowledge, only the study by Neer and Foster⁷² has shown that a criterion for a positive sulcus sign was that it reproduced the patient's symptoms of inferior instability. In our experience, it is uncommon to produce an inferior subluxation of the shoulder in the office using a sulcus sign or to have a patient report that the sulcus sign reproduces their symptoms of instability. Use of these criteria for a positive sulcus sign has apparently not been studied. One study has shown that using a specific magnitude of a sulcus sign on clinical testing (eg, a grade II or III) tends to lead to an overdiagnosis of multidirectional instability.⁶⁵ Similarly, the production of pain with sulcus sign testing has not been studied as a reliable criterion for making the diagnosis of inferior instability. In our experience, pain with sulcus testing can be seen with a variety of shoulder injuries and is not unique to patients with shoulder instability.

If the sulcus sign of the shoulder with the arm in external rotation is greater than that of the arm in neutral rotation, some clinicians believe that surgical repair is indicated.^{15,16,73} However, this criterion for a positive test has not been studied in asymptomatic individuals, and its use for prediction of surgical result has not been validated. Although we recommend performing the sulcus sign in neutral and in external rotation, additional study is needed before it can be recommended definitively for directing treatment.

CONCLUSION

Laxity testing of the shoulder can be a valuable component of the physical examination. Although biomechanical studies have shown that a certain degree of translation cannot define an unstable shoulder, the laxity evaluation can have clinical significance if it reproduces the patient's symptoms of instability. Since laxity testing of the shoulder was first described, clinicians have appreciated that asymmetry in shoulder laxity testing does not verify that the patient's shoulder is unstable,^{21,51,63} and that the ability to sublunate the humeral head over the glenoid rim either anteriorly or posteriorly is essentially a normal variant.^{51,63} These studies show that although laxity testing can provide information about translation of the humeral head, it should reproduce the patient's symptoms of instability to

be clinically useful.^{36,92} Laxity is normal asymptomatic glenohumeral motion, whereas instability is painful, unwanted glenohumeral motion. The use of sulcus testing may indicate inferior laxity, but controlled studies of the effect of surgical procedures addressing inferior laxity are warranted to define more clearly the role of sulcus testing in the assessment and treatment of the symptomatic shoulder.

REFERENCES

1. Altchek DW, Warren RF, Skyhar MJ, Ortiz G. T-plasty modification of the Bankart procedure for multidirectional instability of the anterior and inferior types. *J Bone Joint Surg Am.* 1991;73:105-112.
2. Arendt EA. Multidirectional shoulder instability. *Orthopedics.* 1988;11:113-120.
3. Aston JW, Jr, Gregory CF. Dislocation of the shoulder with significant fracture of the glenoid. *J Bone Joint Surg Am.* 1973;55:1521-1533.
4. Bak K, Spring BJ, Henderson IJP. Inferior capsular shift procedure in athletes with multidirectional instability based on isolated capsular and ligamentous redundancy. *Am J Sports Med.* 2000;28:466-471.
5. Basmajian JV, Bazant FJ. Factors preventing downward dislocation of the adducted shoulder joint: an electromyographic and morphological study. *Am J Orthop.* 1959;41:1182-1186.
6. Blasier RB, Guldberg RE, Rothman ED. Anterior shoulder stability: contributions of rotator cuff forces and the capsular ligaments in a cadaver model. *J Shoulder Elbow Surg.* 1992;1:140-150.
7. Borsa PA, Jacobson JA, Scibek JS, Dover GC. Comparison of dynamic sonography to stress radiography for assessing glenohumeral laxity in asymptomatic shoulders. *Am J Sports Med.* 2005;33:734-741.
8. Borsa PA, Sauers EL, Herling DE, Manzour WF. In vivo quantification of capsular end-point in the nonimpaired glenohumeral joint using an instrumented measurement system. *J Orthop Sports Phys Ther.* 2001;31:419-426.
9. Burkart AC, Debski RE. Anatomy and function of the glenohumeral ligaments in anterior shoulder instability. *Clin Orthop Relat Res.* 2002;400:32-39.
10. Burkhart SS, De Beer JF. Traumatic glenohumeral bone defects and their relationship to failure of arthroscopic Bankart repairs: significance of the inverted-pear glenoid and the humeral engaging Hill-Sachs lesion. *Arthroscopy.* 2000;16:677-694.
11. Burkhart SS, Morgan CD, Kibler WB. Shoulder injuries in overhead athletes: the "dead arm" revisited. *Clin Sports Med.* 2000;19:125-158.
12. Choi CH, Ogilvie-Harris DJ. Inferior capsular shift operation for multidirectional instability of the shoulder in players of contact sports. *Br J Sports Med.* 2002;36:290-294.
13. Cofield RH, Irving JF. Evaluation and classification of shoulder instability, with special reference to examination under anesthesia. *Clin Orthop Relat Res.* 1987;223:32-43.
14. Cofield RH, Nessler JP, Weinstabl R. Diagnosis of shoulder instability by examination under anesthesia. *Clin Orthop Relat Res.* 1993;291:45-53.
15. Cole BJ, Mazzocca AD, Meneghini RM. Indirect arthroscopic rotator interval repair. *Arthroscopy.* 2003;19:E33-E36.
16. Cole BJ, Romeo AA. Arthroscopic shoulder stabilization with suture anchors: technique, technology, and pitfalls. *Clin Orthop Relat Res.* 2001;390:17-30.
17. Cooper RA, Brems JJ. The inferior capsular-shift procedure for multidirectional instability of the shoulder. *J Bone Joint Surg Am.* 1992;74:1516-1521.
18. Court-Payen M, Krarup AL, Skjoldbye B, Lausten GS. Real-time sonography of anterior translation of the shoulder: an anterior approach. *Eur J Ultrasound.* 1995;2:283-287.
19. Curl LA, Warren RF. Glenohumeral joint stability. Selective cutting studies on the static capsular restraints. *Clin Orthop Relat Res.* 1996;330:54-65.

20. Debski RE, Wong EK, Woo SLY, Sakane M, Fu FH, Warner JJP. In situ force distribution in the glenohumeral joint capsule during anterior-posterior loading. *J Orthop Res.* 1999;17:769-776.
21. Ellenbecker TS, Mattalino AJ, Elam E, Caplinger R. Quantification of anterior translation of the humeral head in the throwing shoulder: manual assessment versus stress radiography. *Am J Sports Med.* 2000;28:161-167.
22. Emery RJH, Mullaji AB. Glenohumeral joint instability in normal adolescents. Incidence and significance. *J Bone Joint Surg Br.* 1991;73:406-408.
23. Faber KJ, Homa K, Hawkins RJ. Translation of the glenohumeral joint in patients with anterior instability: awake examination versus examination with the patient under anesthesia. *J Shoulder Elbow Surg.* 1999;8:320-323.
24. Farber AJ, Castillo RC, Clough M, Bahk M, McFarland EG. Clinical assessment of three common tests for traumatic anterior shoulder instability. *J Bone Joint Surg Am.* In press.
25. Ferrari DA. Capsular ligaments of the shoulder: anatomical and functional study of the anterior superior capsule. *Am J Sports Med.* 1990;18:20-24.
26. Frostick SP, Sinopidis C, Al Maskari S, Gibson J, Kemp GJ, Richmond JC. Arthroscopic capsular shrinkage of the shoulder for the treatment of patients with multidirectional instability: minimum 2-year follow-up. *Arthroscopy.* 2003;19:227-233.
27. Gagey OJ, Gagey N. The hyperabduction test. *J Bone Joint Surg Br.* 2001;83:69-74.
28. Georgousis H, Ring D. Radiographic glenohumeral joint translation evaluated with a new positioning device. *J Shoulder Elbow Surg.* 1996;5:S87.
29. Gerber C, Ganz R. Clinical assessment of instability of the shoulder: with special reference to anterior and posterior drawer tests. *J Bone Joint Surg Br.* 1984;66:551-556.
30. Harryman DT II, Sidles JA, Clark JM, McQuade KJ, Gibb TD, Matsen FA III. Translation of the humeral head on the glenoid with passive glenohumeral motion. *J Bone Joint Surg Am.* 1990;72:1334-1343.
31. Harryman DT II, Sidles JA, Harris SL, Matsen FA III. Laxity of the normal glenohumeral joint: a quantitative in vivo assessment. *J Shoulder Elbow Surg.* 1992;1:66-76.
32. Harryman DT II, Sidles JA, Harris SL, Matsen FA III. The role of the rotator interval capsule in passive motion and stability of the shoulder. *J Bone Joint Surg Am.* 1992;74:53-66.
33. Hawkins RJ, Bell RH. Shoulder instability: diagnosis and management. *Can J Sport Sci.* 1987;12:67-70.
34. Hawkins RJ, Bokor DJ. Clinical evaluation of shoulder problems. In: Rockwood CA Jr, Matsen FA III, eds. *The Shoulder.* Philadelphia, PA: WB Saunders Co; 1990:149-177.
35. Hawkins RJ, Bokor DJ. Clinical evaluation of shoulder problems. In: Rockwood CA Jr, Matsen FA III, eds. *The Shoulder.* 2nd ed. Philadelphia, PA: WB Saunders; 1998:164-197.
36. Hawkins RJ, Mohtadi NGH. Clinical evaluation of shoulder instability. *Clin J Sport Med.* 1991;1:59-64.
37. Hawkins RJ, Schutte JP, Janda DH, Huckell GH. Translation of the glenohumeral joint with the patient under anesthesia. *J Shoulder Elbow Surg.* 1996;5:286-292.
38. Helmig P, Sojbjerg JO, Kjaersgaard-Andersen P, Nielsen S, Ovesen J. Distal humeral migration as a component of multidirectional shoulder instability: an anatomical study in autopsy specimens. *Clin Orthop Relat Res.* 1990;252:139-143.
39. Howell SM, Galinat BJ. The glenoid-labral socket: a constrained articular surface. *Clin Orthop Relat Res.* 1989;243:122-125.
40. Hsu AT, Chang JH, Chang CH. Determining the resting position of the glenohumeral joint: a cadaver study. *J Orthop Sports Phys Ther.* 2002;32:605-612.
41. Itoi E, Lee SB, Berglund LJ, Berge LL, An KN. The effect of a glenoid defect on anteroinferior stability of the shoulder after Bankart repair: a cadaveric study. *J Bone Joint Surg Am.* 2000;82:35-46.
42. Jerosch J, Marquardt M, Winkelmann W. [Ultrasound documentation of translational movement of the shoulder joint: normal values and pathologic findings]. *Ultraschall Med.* 1991;12:31-35.
43. Jobe FW, Kvitne RS, Giangarra CE. Shoulder pain in the overhand or throwing athlete: the relationship of anterior instability and rotator cuff impingement. *Orthop Rev.* 1989;18:963-975.
44. Kibler WB. The role of the scapula in athletic shoulder function. *Am J Sports Med.* 1998;26:325-337.
45. Kibler WB, McMullen J, Uhl T. Shoulder rehabilitation strategies, guidelines, and practice. *Orthop Clin North Am.* 2001;32:527-538.
46. Kibler WB, Uhl TL, Maddux JWQ, Brooks PV, Zeller B, McMullen J. Qualitative clinical evaluation of scapular dysfunction: a reliability study. *J Shoulder Elbow Surg.* 2002;11:550-556.
47. Krarup AL, Court-Payen M, Skjoldbye B, Lausten GS. Ultrasonic measurement of the anterior translation in the shoulder joint. *J Shoulder Elbow Surg.* 1999;8:136-141.
48. Krishnan SG, Hawkins RJ, Bokor DJ. Clinical evaluation of shoulder problems. In: Rockwood CA Jr, Matsen FA III, Wirth MA, Lippitt SB, eds. *The Shoulder.* 3rd ed. Philadelphia, PA: WB Saunders; 2004:145-185.
49. Kummel BM. Fractures of the glenoid causing chronic dislocation of the shoulder. *Clin Orthop Relat Res.* 1970;69:189-191.
50. Levy AS, Lintner S, Kenter K, Speer KP. Intra- and interobserver reproducibility of the shoulder laxity examination. *Am J Sports Med.* 1999;27:460-463.
51. Lintner SA, Levy A, Kenter K, Speer KP. Glenohumeral translation in the asymptomatic athlete's shoulder and its relationship to other clinically measurable anthropometric variables. *Am J Sports Med.* 1996;24:716-720.
52. Lippitt S, Matsen F. Mechanisms of glenohumeral joint stability. *Clin Orthop Relat Res.* 1993;291:20-28.
53. Lippitt SB, Harris SL, Harryman DT II, Sidles J, Matsen FA III. In vivo quantification of the laxity of normal and unstable glenohumeral joints. *J Shoulder Elbow Surg.* 1994;3:215-223.
54. Lippitt SB, Vanderhooft JE, Harris SL, Sidles JA, Harryman DT II, Matsen FA III. Glenohumeral stability from concavity-compression: a quantitative analysis. *J Shoulder Elbow Surg.* 1993;2:27-35.
55. Lo IKY, Nonweiler B, Woolfrey M, Litchfield R, Kirkley A. An evaluation of the apprehension, relocation, and surprise tests for anterior shoulder instability. *Am J Sports Med.* 2004;32:301-307.
56. Lo IKY, Parten PM, Burkhart SS. The inverted pear glenoid: an indicator of significant glenoid bone loss. *Arthroscopy.* 2004;20:169-174.
57. Magee DJ. Shoulder. In: Magee DJ, ed. *Orthopedic Physical Assessment.* 4th ed. Philadelphia, PA: WB Saunders; 2002:207-319.
58. Matsen FA III, Harryman DT, II Sidles JA. Mechanics of glenohumeral instability. *Clin Sports Med.* 1991;10:783-788
59. Maki NJ. Cineradiographic studies with shoulder instabilities. *Am J Sports Med.* 1988;16:362-364.
60. Matsen FA III, Thomas SC, Rockwood CA Jr, Wirth MA. Glenohumeral instability. In: Rockwood CA Jr, Matsen FA III, eds. *The Shoulder.* 2nd ed. Philadelphia, PA: WB Saunders; 1998:611-754.
61. Matsen FA III, Titelman RM, Lippitt SB, Rockwood CA Jr, Wirth MA. Glenohumeral instability. In: Rockwood CA Jr, Matsen FA III, Wirth MA, Lippitt SB, eds. *The Shoulder.* 3rd ed. Philadelphia, PA: WB Saunders; 2004:655-794.
62. McFarland EG. Instability and laxity. In: *Examination of the Shoulder: The Complete Guide.* New York, NY: Thieme; 2006:162-212.
63. McFarland EG, Campbell G, McDowell J. Posterior shoulder laxity in asymptomatic athletes. *Am J Sports Med.* 1996;24:468-471.
64. McFarland EG, Hsu CY, Neira C, O'Neil O. Internal impingement of the shoulder: a clinical and arthroscopic analysis. *J Shoulder Elbow Surg.* 1999;8:458-460.
65. McFarland EG, Kim TK, Park HB, Neira CA, Gutierrez MI. The effect of variation in definition on the diagnosis of multidirectional instability of the shoulder. *J Bone Joint Surg Am.* 2003;85:2138-2144.
66. McFarland EG, Park HB, Kim TK, Chronopoulos E, Yokota A. Shoulder problems. In: Speer KP, ed. *Injury Prevention and Rehabilitation for Active Older Adults.* Champaign, IL: Human Kinetics; 2005:89-106.
67. McFarland EG, Torpey BM, Curl LA. Evaluation of shoulder laxity. *Sports Med.* 1996;22:264-272.
68. Millett PJ, Clavert P, Warner JJP. Arthroscopic management of anterior, posterior, and multidirectional shoulder instability: pearls and pitfalls. *Arthroscopy.* 2003;19:86-93.

69. Milne AD, Chess DG, Johnson JA, King GJW. Accuracy of an electromagnetic tracking device: a study of the optimal range and metal interference. *J Biomech.* 1996;29:791-793.
70. Miniaci A, McBirnie J. Thermal capsular shrinkage for treatment of multidirectional instability of the shoulder. *J Bone Joint Surg Am.* 2003;85:2283-2287.
71. Morgan CD, Burkhart SS, Palmeri M, Gillespie M. Type II SLAP lesions: three subtypes and their relationships to superior instability and rotator cuff tears. *Arthroscopy.* 1998;14:553-565.
72. Neer CS, II, Foster CR. Inferior capsular shift for involuntary inferior and multidirectional instability of the shoulder: a preliminary report. *J Bone Joint Surg Am.* 1980;62:897-908.
73. Nobuhara K, Ikeda H. Rotator interval lesion. *Clin Orthop Relat Res.* 1987;223:44-50.
74. Norris TR. Diagnostic techniques for shoulder instability. *Instr Course Lect.* 1985;34:239-257.
75. O'Brien SJ, Neves MC, Arnoczky SP, et al. The anatomy and histology of the inferior glenohumeral ligament complex of the shoulder. *Am J Sports Med.* 1990;18:449-456.
76. Oliashirazi A, Mansat P, Cofield RH, Rowland CM. Examination under anesthesia for evaluation of anterior shoulder instability. *Am J Sports Med.* 1999;27:464-468.
77. Ovesen J, Nielsen S. Anterior and posterior shoulder instability: a cadaver study. *Acta Orthop Scand.* 1986;57:324-327.
78. Ovesen J, Nielsen S. Experimental distal subluxation in the glenohumeral joint. *Arch Orthop Trauma Surg.* 1985;104:78-81.
79. Ovesen J, Nielsen S. Posterior instability of the shoulder: a cadaver study. *Acta Orthop Scand.* 1986;57:436-439.
80. Ovesen J, Nielsen S. Stability of the shoulder joint: cadaver study of stabilizing structures. *Acta Orthop Scand.* 1985;56:149-151.
81. Pagnani MJ, Warren RF. Stabilizers of the glenohumeral joint. *J Shoulder Elbow Surg.* 1994;3:173-190.
82. Papilion JA, Shall LM. Fluoroscopic evaluation for subtle shoulder instability. *Am J Sports Med.* 1992;20:548-552.
83. Pollock RG, Owens JM, Flatow EL, Bigliani LU. Operative results of the inferior capsular shift procedure for multidirectional instability of the shoulder. *J Bone Joint Surg Am.* 2000;82:919-928.
84. Reis MT, Tibone JE, McMahon PJ, Lee TQ. Cadaveric study of glenohumeral translation using electromagnetic sensors. *Clin Orthop Relat Res.* 2002;400:88-92.
85. Rowe CR, Zarins B. Recurrent transient subluxation of the shoulder. *J Bone Joint Surg Am.* 1981;63:863-872.
86. Rubin BD, Kibler WB. Fundamental principles of shoulder rehabilitation: conservative to postoperative management. *Arthroscopy.* 2002;18:29-39.
87. Sauers EL, Borsa PA, Herling DE, Manzour WF, Stanley RD. Validity of an instrumented measurement technique for quantifying glenohumeral joint laxity and stiffness. *J Athletic Training.* 2001;36:S40.
88. Sauers EL, Borsa PA, Herling DE, Stanley RD. Instrumented measurement of glenohumeral joint laxity and its relationship to passive range of motion and generalized joint laxity. *Am J Sports Med.* 2001;29:143-150.
89. Sauers EL, Borsa PA, Herling DE, Stanley RD. Instrumented measurement of glenohumeral joint laxity: reliability and normative data. *Knee Surg Sports Traumatol Arthrosc.* 2001;9:34-41.
90. Schwartz RE, O'Brien SJ, Warren RF, Torzilli PA. Capsular restraints to anterior-posterior motion of the shoulder. *Orthop Trans.* 1988;12:727.
91. Silliman JF, Hawkins RJ. Classification and physical diagnosis of instability of the shoulder. *Clin Orthop Relat Res.* 1993;291:7-19.
92. Silliman JF, Hawkins RJ. Current concepts and recent advances in the athlete's shoulder. *Clin Sports Med.* 1991;10:693-705.
93. Smith SP, Bunker TD. Primary glenoid dysplasia: a review of 12 patients. *J Bone Joint Surg Br.* 2001;83:868-872.
94. Speer KP, Deng X, Borrero S, Torzilli PA, Altchek DA, Warren RF. Biomechanical evaluation of a simulated Bankart lesion. *J Bone Joint Surg Am.* 1994;76:1819-1826.
95. Terry GC, Hammon D, France P, Norwood LA. The stabilizing function of passive shoulder restraints. *Am J Sports Med.* 1991;19:26-34.
96. Tibone JE, Lee TQ, Csintalan RP, Dettling J, McMahon PJ. Quantitative assessment of glenohumeral translation. *Clin Orthop Relat Res.* 2002;400:93-97.
97. Tillander B, Norlin R. Intraoperative measurement of shoulder translation. *J Shoulder Elbow Surg.* 2001;10:358-364.
98. Trout TE, Resnick D. Glenoid hypoplasia and its relationship to instability. *Skeletal Radiol.* 1996;25:37-40.
99. Turkel SJ, Panio MW, Marshall JL, Girgis FG. Stabilizing mechanisms preventing anterior dislocation of the glenohumeral joint. *J Bone Joint Surg Am.* 1981;63:1208-1217.
100. Tzannes A, Murrell GAC. Clinical examination of the unstable shoulder. *Sports Med.* 2002;32:447-457.
101. Tzannes A, Paxinos A, Callanan M, Murrell GAC. An assessment of the interexaminer reliability of tests for shoulder instability. *J Shoulder Elbow Surg.* 2004;13:18-23.
102. Warner JJP, Deng XH, Warren RF, Torzilli PA. Static capsuloligamentous restraints to superior-inferior translation of the glenohumeral joint. *Am J Sports Med.* 1992;20:675-685.
103. Warren RF, Kornblatt IB, Marchand R. Static factors affecting posterior shoulder stability. *Orthop Trans.* 1984;8:89.
104. Wilk KE, Andrews JR, Arrigo CA. The physical examination of the glenohumeral joint: emphasis on the stabilizing structures. *J Orthop Sports Phys Ther.* 1997;25:380-389.
105. Wirth MA, Lyons FR, Rockwood CA Jr. Hypoplasia of the glenoid: a review of sixteen patients. *J Bone Joint Surg Am.* 1993;75:1175-1184.
106. Wuelker N, Schmotzer H, Thren K, Korell M. Translation of the glenohumeral joint with simulated active elevation. *Clin Orthop Relat Res.* 1994;309:193-200.
107. Yoldas EA, Faber KJ, Hawkins RJ. Translation of the glenohumeral joint in patients with multidirectional and posterior instability: awake examination versus examination under anesthesia. *J Shoulder Elbow Surg.* 2001;10:416-420.