


Robert J. Meislin
Jeffrey Halbrecht *Editors*

Complications in Knee and Shoulder Surgery



Management and Treatment Options for
the Sports Medicine Orthopedist

 Springer

Chapter 11

Avoiding and Managing Complications for Shoulder Superior Labrum (SLAP) Repair

Michael S. Bahk and Stephen J. Snyder

Top 10 Pearls

- The diagnosis of SLAP lesions can be challenging. There is no specific test or imaging study that is perfect. Arthroscopy is the key when the clinical situation requires a remedy.
- SLAP lesions often have additional pathology.
- There are numerous anatomic variants that can be confused for SLAP lesions, and they must be understood to avoid misdiagnosis and treatment.
- Creation of the anterosuperior portal is critical and allows proper anchor placement. The ideal location is superior to the biceps tendon at the posterior aspect of the rotator interval. Use a spinal needle for an outside-in technique.
- Avoid rotator cuff injury with the anterior superior portal.
- Place the punch or drill posterior to the biceps and angle it directly into the bone at the center of the biceps tubercle.
- The punch must ideally penetrate the superior glenoid exactly at the center of the biceps anchor just below the edge of the cartilage at an angle of 45° relative to the glenoid surface.
- One low profile double-loaded suture anchor with a suture anterior and one posterior to the biceps is typically sufficient and ideal.
- Do not leave any anchors proud.
- Use a 15° external rotation sling with no aggressive

Introduction and Background

Clinically significant injuries to the superior labrum are uncommon. Most arthroscopic shoulder series report an incidence around 6%.¹⁻³ In 1985, Andrews et al. described tears of the anterosuperior labrum in 73 overhead athletes.⁴ They recommended debridement alone as an effective treatment but made no mention or need for fixation of the biceps anchor. Snyder et al. in 1990 first described superior labral and biceps anchor pathology as a Superior Labrum Anterior and Posterior (SLAP) lesions. They characterized and classified these lesions as injuries occurring posteriorly, extending anteriorly to *and including* the biceps anchor.¹ Subsequent laboratory studies have defined the biomechanical importance of the biceps anchor,⁵⁻¹⁰ while clinical data report significant pain and prolonged disability in patients with untreated SLAP tears.^{1,2,4} However, diagnosis of SLAP lesions is still challenging even when based on history, physical examination, and modern imaging modalities. Knowledge of the numerous normal anatomic variations diminishes the likelihood of over diagnosis of SLAP tears and unnecessary surgical treatment of normal anatomy. Proper surgical repair technique requires understanding and arthroscopic skill and is fraught with potential complications.

Functional Anatomy at Risk

in 73% of shoulders.¹³⁻¹⁵ The sublabral recess is most common at the 12 o'clock position and decreases in incidence inferiorly.¹⁵ The superior labrum is also more mobile with variable attachment in the anterosuperior quadrant. Conversely, the inferior labrum is rounded, firmly attached, and continuous with the glenoid.¹⁴ Cooper et al. felt that the superior labrum may act as a mobile extension of the superior glenoid, while the inferior labrum may act as a stabilizing bumper.¹⁴

The long head of the biceps tendon originates from the superior labrum and supraglenoid tubercle in varying degrees.^{11,16,17} However, the biceps arises predominantly from the labrum with little contribution from the supraglenoid tubercle in some shoulders.^{11,16} The supraglenoid tubercle lies 5 mm medial to the superior glenoid rim.^{11,17} The biceps origin may vary from the 11-1 o'clock position; however, in 55% of shoulders it arises posteriorly. It has an equal anterior and posterior origin in 37% of shoulders.¹⁷

The superior glenohumeral ligament predominantly arises from the supraglenoid tubercle with some fibers arising from the biceps-superior labral origin.¹⁵ The middle glenohumeral ligament attachment is variable. It may arise from the superior labrum at the biceps anchor, the anterior superior glenoid, or the adjacent labrum, and is described as sheet-like typically and obliquely draped over the subscapularis tendon.¹⁸

There are three normal variations of the anterosuperior quadrant of the glenoid having an overall incidence of 13-14%.^{19,20} The most common variation is a sublabral foramen (9%) with a cord-like middle glenohumeral ligament attaching directly to the anterosuperior labral tissue.^{19,20} Three percent of shoulders have a sublabral foramen and 1.5% include a Buford complex. This important variation consists of complete absence of all anterosuperior labral tissue but possesses a robust cord-like middle glenohumeral ligament that attaches directly to the base of the biceps tendon/labral junction.^{19,20} It is important to understand these normal variations to avoid over diagnosis of SLAP lesions or "repair" of normal anatomy, which may severely restrict motion.

The blood supply of the labrum is peripherally based and predominately radial in flow. It originates from the surrounding periosteum and capsule and not from the underlying bone.¹⁴ The anterosuperior and superior labrum have less vascularity compared with the rest of the labrum.¹⁴ The blood supply ultimately originates from the suprascapular, circumflex scapular,

and posterior circumflex humeral arteries.¹⁴ Vascularity decreases with increasing age.^{11,12}

Biomechanics

The long head of the biceps and its glenoid-labral anchor contribute to the stability of the glenohumeral joint. Biomechanical studies have shown that a competent biceps labral complex provides translational and rotational stability. Proper repair of a SLAP tear should restore normal biomechanics.²¹

With biceps contraction, the short head causes proximal humeral migration. However, this is counterbalanced by the biceps long head contraction, which results in humeral head depression. With elbow flexion and supination, release of the long head of the biceps results in proximal humeral migration by 15.5%.⁵

In the abducted externally rotated position, the shoulder is vulnerable to anterior dislocation. At 90° abduction, increased biceps tension significantly reduces anterior displacement at 60° and 90° of external rotation.⁶ With 120° external rotation, increased biceps tension reduces anterior displacement when a Bankart lesion is present.⁶ In other words, biceps contraction helps to stabilize the unstable shoulder anteriorly. Similarly, EMG studies have reported peak biceps activity in the late cocking phase of throwing for pitchers and noted higher biceps activity in pitchers with known chronic anterior instability.^{7,8} Rodosky et al. also reported that creation of a SLAP lesion in a cadaveric model decreases anterior shoulder stability by decreasing torsional rigidity in the overhead position. They also reported that a SLAP tear increases inferior glenohumeral strain.⁹

Pagnani et al. reported increased superoinferior and anteroposterior translation in the lower and middle ranges of abduction with a SLAP lesion.¹⁰ Detachment of the superior labrum with its concomitant superior and middle glenohumeral ligaments may help explain the increase in translation. In addition, loss of an intact labral complex reduces concavity compression with loss of biceps contraction.¹⁰

Similarly, Panossian et al. reported SLAP tears increased anteroposterior and superoinferior translation along with increased external rotation in a cadaveric model. Arthroscopic repair was able to return range of

motion to normal levels afterwards without the need for additional capsular plication.²¹

Classification

In 1990, Snyder et al. classified SLAP tears into four types (Fig. 11.1a-d).¹ There have been numerous additions to this classification system since then.²²⁻²⁴

Type I lesions have degenerative fraying but the labrum and biceps anchor are firmly attached to the glenoid. Snyder reported a 21% incidence in their study population.² This lesion is part of the degenerative process and more common in middle-aged to older patients. It is a possible but uncommon source of clinical symptoms.

Type II lesions are the most common lesion (55%) and represent a significant detachment of the biceps labral anchor from the glenoid.² The superior and middle

glenohumeral ligaments may be detached as well, so evaluation for instability is important.

Type III lesions occurred in 9% of the study population.² This lesion includes a bucket-handle tear of a meniscoid superior labrum. The biceps is normal and firmly attached to the rest of the labrum and supraglenoid tubercle. Type IV lesions occur in 10% of patients and consists of a bucket-handle tear of the meniscoid superior labrum with extension of the tear into the biceps tendon.²

There may be complex SLAP tears or combinations of these lesions. Most commonly, type III and type IV tears may have detached biceps anchors or a type II component. They can be described as type II and III or type II and IV.²⁵

Type II SLAP tears have also been subclassified into three groups by Morgan et al. as anterior, posterior, and combined anterior and posterior lesions.²² Type II SLAP tears with posterior extension more commonly occurred in younger overhead or throwing

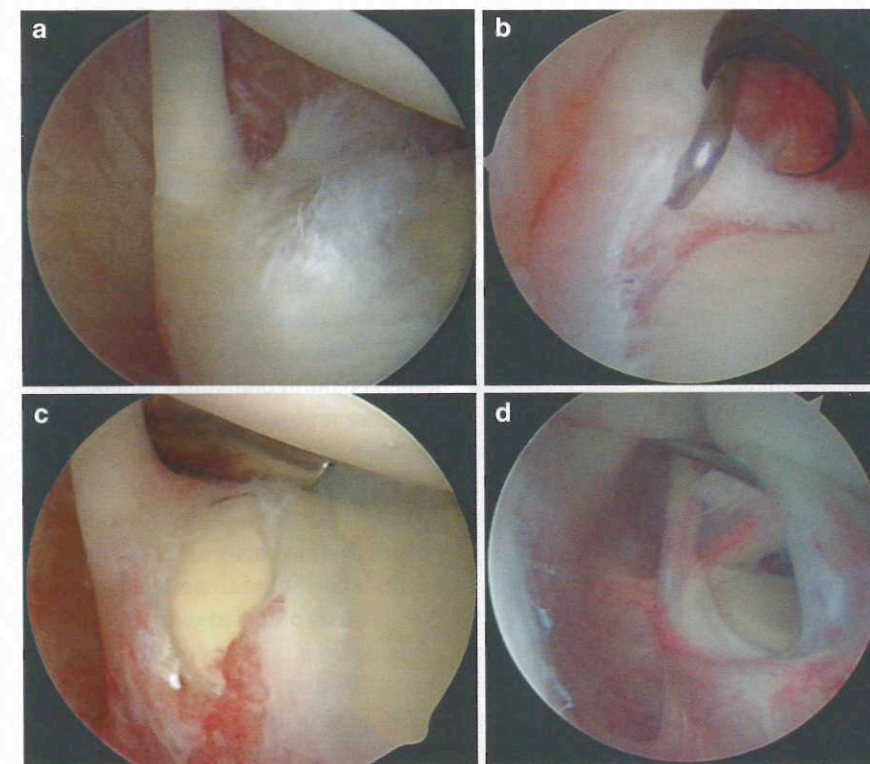


Fig. 11.1 SLAP lesion types I-IV. (a) Type I SLAP lesion with degenerative fraying of the superior labrum and biceps anchor. (b) Type II SLAP lesion with complete detachment of the biceps anchor from the superior glenoid. (c) Type III SLAP lesion with

a bucket-handle tear of the superior labrum. (d) Type IV SLAP lesion with a bucket-handle tear of the superior labrum that extends into the biceps tendon

athletes and may occur by a peel-back mechanism.^{22,26} These patients also possessed a drive-through sign that corrected after repair. Morgan et al. felt these SLAP lesions created a posterosuperior instability or laxity that may lead to additional injuries such as posterior partial thickness rotator cuff tears.²²

Additional SLAP types have been added describing various extensions of the superior labral tear.^{23,27} The SLAP tear may continue anteroinferiorly into a Bankart lesion, posteriorly, circumferentially or into the middle glenohumeral ligament.^{23,27}

Diagnosis

History

The diagnosis of SLAP tears can be difficult since it is often associated with additional shoulder pathologies. The history can be nonspecific with patients reporting prolonged, vague shoulder pain, or disability that does not improve with conservative management and is exacerbated with overhead activity.¹ They may complain of mechanical symptoms if a torn fragment is trapped between the humerus and glenoid.¹ Snyder et al. reported 49% of patients noted mechanical catching or grinding.² SLAP tears have a high incidence of associated shoulder pathologies including instability, rotator cuff tears, and ganglion cyst formation complicating diagnosis.¹ One large series reported 40% of SLAP lesions were associated with either full or partial thickness rotator cuff tears, while 22% of lesions were associated with Bankart lesions.² Only 28% of SLAP lesions were isolated lesions.²

The typical patient is a young male that either describes a traumatic origin or one associated with chronic overhead activity. Snyder et al. reported an average age of 38 years with 91% of the patients being male.¹⁻³ Traumatic injuries often occur with either a compressive injury such as a fall onto an outstretched arm or a traction mechanism of injury from a sudden pull on the arm.^{1,23,28-30} Cadaveric models have confirmed reproducible creation of SLAP tears with these traumatic mechanisms.^{29,30} Patients with SLAP tears associated with overhead activity may present a distinct group with different characteristics. The "dead arm" symptom or the sudden painful inability to throw a ball with usual velocity may be a result of SLAP

lesions.³¹ Morgan et al. reported patients with throwers' SLAP tears or posterior SLAP lesions were younger with an average age of 24 years. It is hypothesized their tears occurred with a peel-back phenomenon as the labrum undergoes pathological torsion in the abducted externally rotated throwing motion.²²

Physical Exam

The physical diagnosis of SLAP tears can be also difficult and nonspecific. No test or combination of tests appears specific for a superior labral injury.^{1,2,25,27,28} Patients also often have positive signs because of associated pathologies.² Snyder et al. reported that 47% of patients had positive impingement signs, 39% had rotator cuff signs, 16% had anterior instability, and 15% had acromioclavicular signs.²

Multiple tests have been reported with varying degrees of accuracy.^{27,28,32-36} Tests commonly used to diagnose SLAP tests include Speed's test, O'Brien's test, compression-rotation test, Kibler's anterior slide test, crank test, and Kim's biceps load tests.^{1,2,27,28,32-37} Snyder et al. originally reported that the Speed's test and the compression-rotation test may be helpful in diagnosis of SLAP tears.¹ Although Speed's test is used to test the biceps tendon, an unstable biceps origin will also illicit symptoms. The patient resists downward pressure with the arm in 90° forward flexion, full elbow extension, and the forearm supinated. The compression rotation test is performed with compressing or loading the glenohumeral joint axially and rotating the humerus to trap loose labrum within the joint. A painful clunk may be noted with a tear.^{1,25} The literature reports good results with O'Brien's test and this may be useful.^{22,25,32} With the arm in 90° forward flexion and 10° adduction, downward pressure is applied with the patient resisting with the forearm pronated and the forearm supinated. A positive test occurs when pain is reported deep in the shoulder with the forearm pronated and relieved with the forearm supinated.³² Kim's biceps load test may also be useful for SLAP diagnosis.³³ The patient's arm is abducted 120°, maximally externally rotated with the elbow in 90° flexion and full forearm supination. The patient flexes the elbow against the examiner. The test is positive with pain production. A variation of this test may also be useful in patients with concomitant anterior instability.³⁴

Morgan et al. reported that anterior SLAP tears could be distinguished from posterior SLAP tears with different physical exam tests.²² Speed's and O'Brien's tests were accurate for anterior lesions, while Jobe's relocation test was sensitive and specific for posterior lesions.²²

It is important to examine for signs of associated pathology. In addition to instability, impingement, and rotator cuff tear signs, careful observation and inspection of shoulder musculature and strength testing may reveal weakness and atrophy associated with supracapular nerve impingement from ganglion cysts associated with labral tears.^{18,25}

Imaging

MRI is currently the best imaging modality for diagnosing SLAP tears. A glenohumeral injection of gadolinium for an MR arthrogram improves diagnostic accuracy.^{38,39} However, MR detection of SLAP tears is not without some difficulty. In 1995, Snyder et al. reported the radiologic diagnosis of SLAP tears as inconsistent with only 26% of MRI radiology readings suggestive of SLAP tears.² MR technology and detection of SLAP tears has improved, with the current literature reporting a sensitivity of 75-98% and a specificity of 69-99%⁴⁰ for MRI/MR arthrograms. However, the MR detection of the community radiologist for a SLAP tear may be lower with an overall accuracy of 51%.⁴⁰ The superior labrum has a unique anatomy with a number of normal anatomic variants that can be diagnostically challenging. In addition, there is some controversy in the radiology literature on accurate signs for distinguishing normal anatomy from a pathological SLAP tear.^{13,41-43}

The normal labrum is characterized by a low signal on all MR pulse sequences. It is usually triangular or rounded in shape.³⁹ The superior labrum is best visualized on coronal oblique images while the anterior and posterior labrum is most easily seen on axial images.³⁹ A SLAP tear can be best visualized on the coronal oblique images with T2, gradient echo or T1 weighted imaging after intraarticular gadolinium injection.^{38,39}

The normal sublabral recess of the superior glenoid-labral complex can be confused for a SLAP tear on MRI. The superior labrum may be meniscoid or possess

a sublabral recess in 73% of shoulders. This sublabral recess can be deeper than 5 mm in 27% of shoulders.¹³ It often appears as a thin, linear signal that follows the normal contour of the glenoid or extends medially. The sublabral recess may exist throughout the superior glenoid-labral complex or exist posterior to the biceps anchor. Any superior signal posterior to the biceps anchor is not necessarily pathological.⁴¹⁻⁴³ The inferior labrum tends to be more rounded and inserts directly onto the glenoid without a recess.

Signal direction, morphology, and width help distinguish a normal sublabral recess signal from a SLAP tear. A SLAP tear is characterized by a wide (≥ 3 mm), ragged signal that extends laterally (Fig. 11.2). The SLAP tear would have indistinct or fuzzy borders because of torn fibers and be wider than the crisp linear normal sublabral recess as fluid or contrast fills the pathologic void. However, following the direction of the signal on coronal oblique pulse sequences appears to be one of the better signs for a SLAP tear.⁴² This lateral signal direction sign has a sensitivity, specificity, and positive predictive value of 81%, 53%, and 50%.⁴²

This pathological signal can extend partially through the superior labrum as a partial tear or propagate full thickness dividing the labrum into a bucket handle tear.³⁹ A type II SLAP tear or full detachment may also be noted when the superior labrum is completely separated from the glenoid. Jin et al. report concomitant

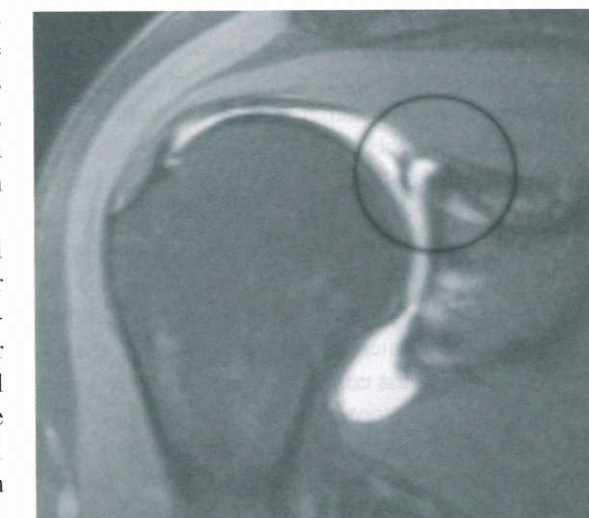


Fig. 11.2 MR arthrogram coronal image with a type II SLAP lesion. The circle denotes the wide signal with lateral extension characteristic of a SLAP lesion

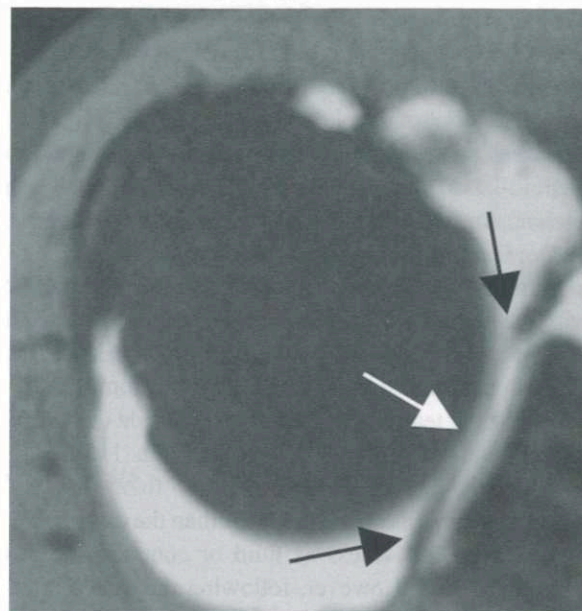


Fig. 11.3 MR arthrogram axial image with a type III SLAP lesion

anterosuperior labral tears and axial images that are able to detect a signal anterior and posterior to the biceps are also helpful in distinguishing a SLAP from a normal sublabral recess (Fig. 11.3).⁴²

The anterosuperior labral normal variants can also be confused with a SLAP tear. Carefully evaluating the suspected tear on sequential MRI images will help identify the location of the signal in question. Evaluating the morphology of the signal in conjunction with location will help distinguish normal variant from SLAP tear. Tears will often have wider signals with ragged borders. The sublabral foramen will demonstrate a smooth narrow signal that is localized to the anterosuperior glenoid with labrum that is firmly attached superiorly and at the midglenoid notch. A Buford complex will show a localized absence of labral tissue in the anterosuperior glenoid with normal cartilage and a robust cord-like middle glenohumeral ligament (Fig. 11.4).

Ganglion cysts have also been associated with labral tears and most commonly with SLAP lesions.^{44,45} Spinoglenoid cysts visualized on coronal or sagittal T2 weighted images should prompt an evaluation for a SLAP tear (Fig. 11.5). Westerheide et al. reported on 14 patients with spinoglenoid cysts treated arthroscopically.

Eighty-six percent of these cysts were found to be associated with labral pathology.⁴⁴

MR arthrography is the best imaging modality for SLAP diagnosis but its accuracy is dependent on a number of factors, especially in the community setting. Knowledge of normal anatomy, normal anatomic variants, and carefully evaluating signal direction, width, and morphology will help correctly identify SLAP tears.

Arthroscopic Diagnosis of SLAP Tears

Arthroscopy is the gold standard for diagnosing SLAP tears. History and physical examination are nonspecific and MRI can be helpful but often misleading. A thorough systematic inspection of the glenohumeral joint anteriorly and posteriorly is ultimately necessary to diagnose a SLAP tear. A probe or grasper must be used to physically examine the superior labrum for any detachment. An unstable biceps anchor will displace when pulled and arch away from the superior glenoid 5 mm or more.²⁵ The glenoid articular cartilage normally extends medially over the superior glenoid through a sublabral recess. Hemorrhage, fraying, granulation tissue, or an unusually deep cleft may be signs of a SLAP tear.²⁵ Normal sublabral holes, cord-like middle glenohumeral ligaments and Buford complexes will similarly appear without significant fraying or hemorrhage. Repair of these normal variants will result in stiff painful shoulders limiting elevation and external rotation. If pulling on the biceps anchor tensions the anterosuperior labrum, superior or middle glenohumeral ligaments, or Buford complex, then a SLAP tear is possible. In addition, posterior SLAP tear subtypes may displace with a peelback maneuver if the arm is taken into abduction and external rotation.^{22,26} A positive "drive-through sign" or being able to move the arthroscope from superiorly to inferiorly, may also indicate laxity of the ligament support function from a SLAP tear.⁴⁶

History of Repairs

Type II SLAP lesions were initially treated with simple debridement and abrasion of the bone in an attempt to

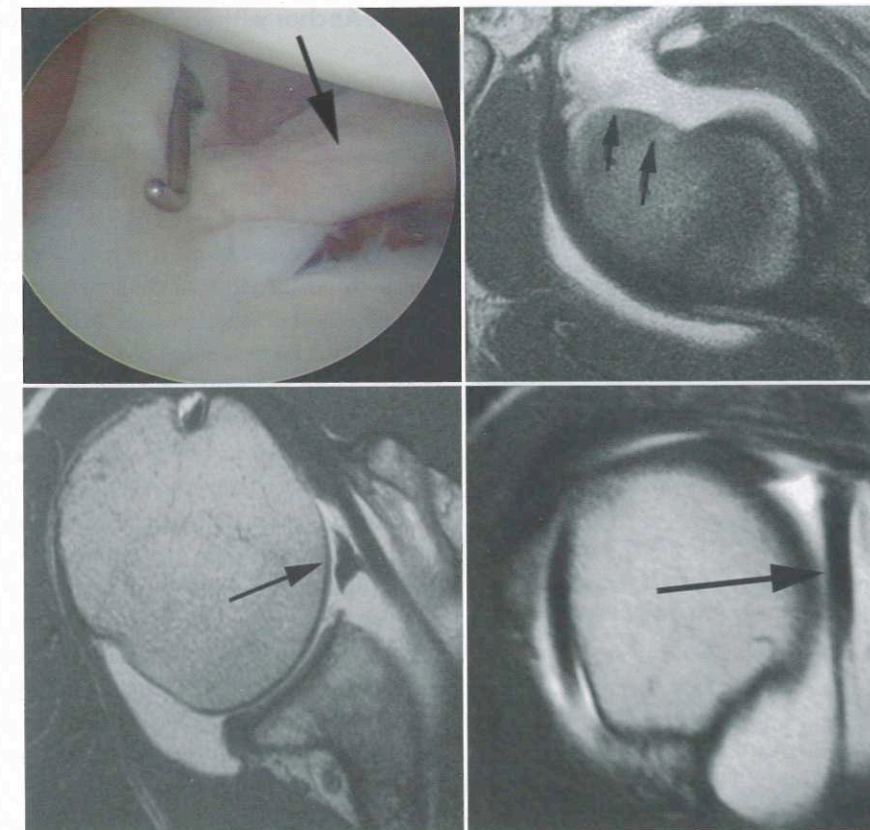


Fig. 11.4 Buford complex with complete absence of anterosuperior labral tissue (double arrows) and a robust cordlike middle glenohumeral ligament (single arrows)

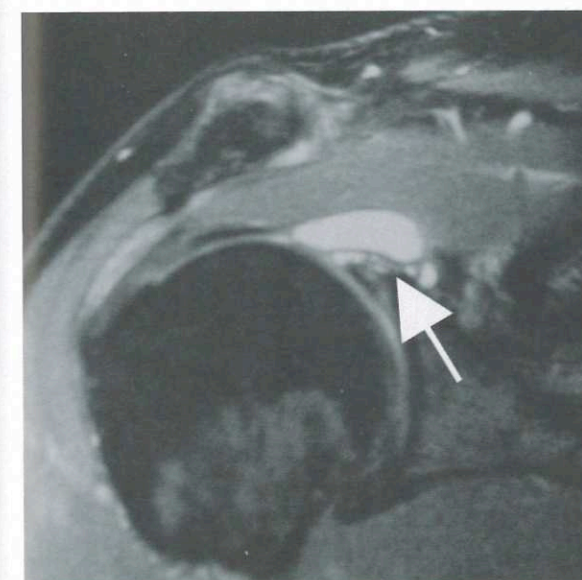


Fig. 11.5 MRI coronal image with arrow highlighting a ganglion cyst that is associated with a SLAP lesion

promote bony healing of the labrum. On second look arthroscopy of five of these abrasion treated lesions, 40% had not healed.² Subsequently, a number of different fixation techniques were developed including staples, transosseous sutures, cannulated screw fixation, and bioabsorbable tacks.^{2,10,47,48} However, these different techniques often required additional surgery for prominent hardware removal or loose bioabsorbable fragments. These problems begat the development of screw-in suture anchors.² Treatment of Type II SLAP lesions has evolved currently utilizing small suture anchors that are double loaded. Because the bone is dense, a small threaded suture anchor provides adequate purchase without being too prominent in a small target area within the biceps anchor origin. One suture limb fixes the biceps anchor anteriorly, while the other is tied posteriorly, providing secure central fixation (Fig. 11.6). Biomechanical data with this repair technique called the "stitch of Burns" revealed significant improvement in strain failure (>2 mm displacement)

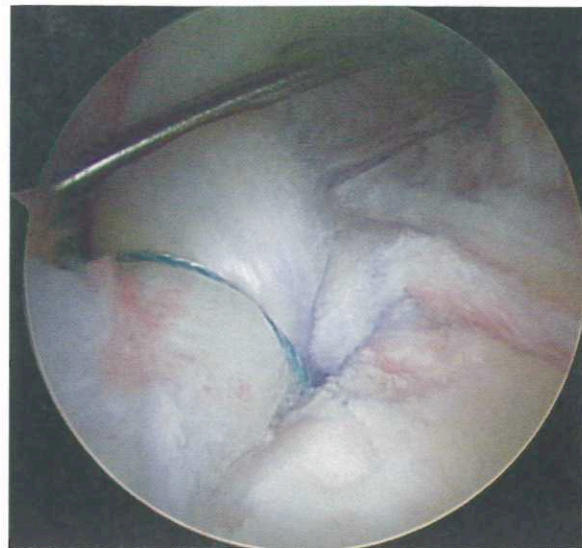


Fig. 11.6 SLAP repair with one central anchor that is double loaded. One suture is anterior and one is tied posterior to the biceps anchor

compared with a 2 anchor repair with an anchor anterior and one posterior to the biceps origin.⁴⁹ Central anchor placement for biceps fixation is key. A double loaded anchor will then provide adequate anterior and posterior biceps anchor security with one pass.

SCOI Repair Technique and Avoiding Complications⁵⁰

Preoperative Discussion

Sometimes the biceps tendon is very degenerative at the attachment to the superior labrum. Fixing a detached anchor will still leave this pathology. It is prudent to discuss with the patient preoperatively the possibility of needing to perform either a tenodesis or tenotomy if this situation is encountered. Any significant fraying of the tendon should be considered for tenodesis or tenotomy. If the labrum is repaired, the biceps tendon may continue to be painful.

Single Anchor with Double Suture SLAP Repair

Establishment of Portals

With the arthroscope in the standard posterior portal, the anterior superior portal (ASP) is created with an outside-in technique. Use a spinal needle to determine the ideal location. Insert it approximately 2 cm from the anterolateral corner of the acromion so that it enters the joint in the superior edge of the rotator interval behind the biceps tendon. Insure that the needle can readily reach the superior neck of the glenoid when passing posterior to the biceps (Fig. 11.7). Portal location is critical for proper anchor placement while avoiding injury to the anterior edge of the supraspinatus tendon. After making an incision using a #11 blade in Langer's lines, insert a clear, smooth, plastic 6-mm operating cannula along the chosen path.

Care must be taken when inserting the anterior superior portal. Only the smallest possible cannula should be used that will permit passing the Crescent suture hook (Linvatec Inc, Largo, FL). One should never pass the cannula through the rotator cuff as has been suggested in some studies.

Next, create an anterior midglenoid portal (AMG) with the same outside-in technique as above, entering through the midpoint of the rotator interval above the subscapularis tendon.

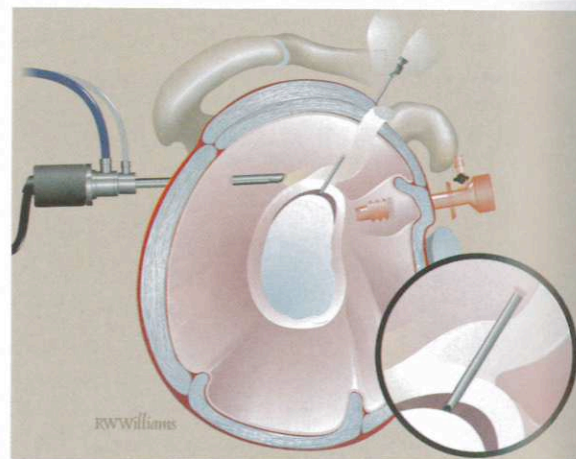


Fig. 11.7 Anterior superior portal placement is critical. Use a spinal needle to confirm access to the biceps anchor origin on the superior glenoid

Prepare the Labrum/Glenoid and Cyst Decompression

Debride any remaining soft tissue off the superior glenoid below the detached labrum/biceps anchor and trim any fraying of the labrum using a 4.2 mm motorized shaver (Fig. 11.8). The posterior portion of the lesion and glenoid is best trimmed with the shaver in the posterior portal and the arthroscope anteriorly. The superior glenoid rim and neck are only slightly decorticated, taking care not to remove excessive bone. The bone here is often relatively soft and use of a burr is seldom necessary.

If any associated spinoglenoid cysts are present, they may likewise be decompressed at this time. The portals dictated for SLAP repair are sufficient for cyst access. Visualization through the ASP and careful attention to the posterosuperior glenoid will help identify the capsular prominence of a cyst. The orifice to the cyst may be also identified under the labrum. We prefer to marsupialize these cysts by opening up the superior capsule adjacent to the labrum. This area is typically posterior to the biceps tendon at the 10:30 or 1:30 o'clock position and delineated by the MRI. Use a shaver with low suction strength or an electrosurgical instrument to open the capsule and gently remove enough wall to prevent closure and recurrence. Amber fluid will spill into the joint upon cyst entry. Cyst wall excision should be performed within a safety margin of approximately 1.5 cm medially from the glenoid rim. The infraspinatus branch of the suprascapular nerve

lies 1.8-2.1 cm from the glenoid rim near the scapular spine.^{51,52} Aggressive exploration and debridement of the cyst under the labrum may endanger the residual biceps anchor and may not allow sufficient decompression.

Anchor Placement

Insert a 2 mm Revo® punch into the ASP, passing posterior to the biceps tendon to create a pilot hole for the 4 mm Big Eye Revo® anchor loaded with two #2 polyethylene sutures (Linvatec Inc, Largo, FL). The punch must penetrate the superior glenoid exactly at the center of the biceps anchor just below the edge of the cartilage at an angle of 45° relative to the glenoid surface. Extreme caution must be exercised to insure the punch is completely within the bone (Fig. 11.9). If the starter punch is not aligned at the proper angle to the superior glenoid surface, it can very easily skive off into the superior glenoid recess or breach the posterior superior glenoid cortex or pass under the articular cartilage. The punch is carefully advanced under direct vision until the pilot hole is completed. The anchor must follow the pilot hole exactly and be carefully observed once it is seated. The biceps origin is not large and will not tolerate multiple attempts. One anchor is typically enough for type II SLAP lesions.

A titanium 4 × 12 mm² screw anchor or similar small double loaded absorbable anchor is preferred.

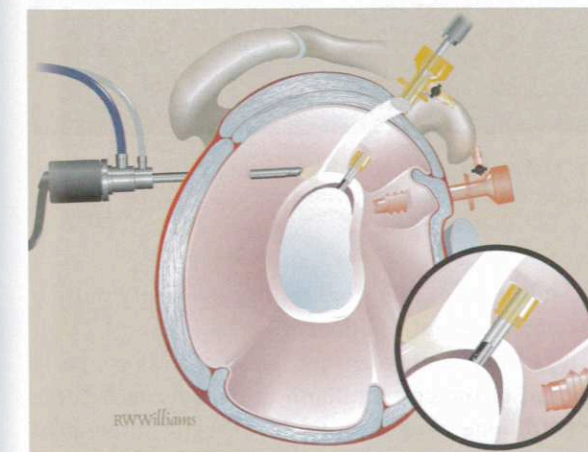


Fig. 11.8 The superior glenoid is gently debrided. A shaver is sufficient and a burr is not necessary because the bone is often relatively soft

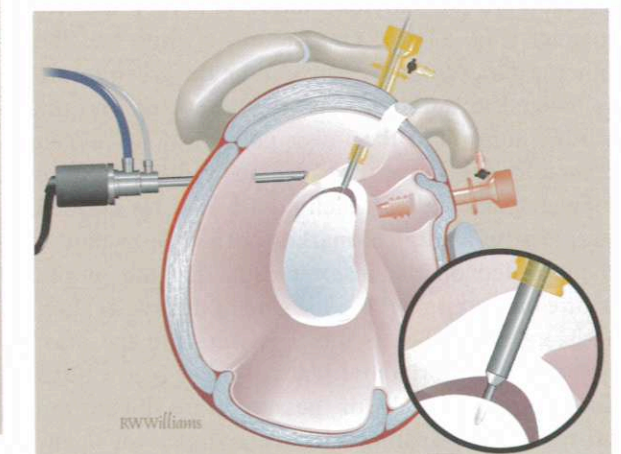


Fig. 11.9 Pass the punch posterior to the biceps at the center of the biceps origin under direct visualization




Fig. 11.10 Big Eye Revo (Linvatec Inc, Largo, FL) metal suture anchor that is double loaded with #2 braided sutures. Half of each suture has been colored purple denoting the limb to be used as the post on the labral side away from the glenohumeral joint

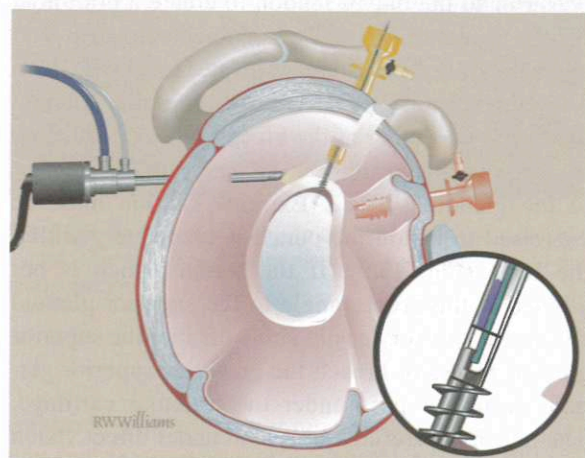


Fig. 11.11 A double loaded suture anchor is placed at the biceps origin

If a bioabsorbable anchor is used, all steps for the implant (punching, drilling, tapping, etc.) should be fully carried out to ensure smooth implantation without implant breakage. The vertically oriented eyelet is first loaded with two strands of nonabsorbable #2 polyethylene suture in a very specific manner (Fig. 11.10). One suture is white and the other is dark green. By convention, the green suture is located at the upper end of the eyelet, and the white suture is at the lower portion of the eyelet closer to the screw threads. To facilitate suture management, half of each suture limb is colored purple with a surgical marking pen. The anchor is then loaded on the inserter such that the purple suture ends exit on the same side of the eyelet (Fig. 11.11). The anchor is then inserted into the pilot hole until the horizontal seating line is below bone and the purple limbs of the suture are toward the biceps tendon. Seating the anchor so that the opening of the eyelet is toward the biceps allows easier sliding of suture. The screwdriver is removed and

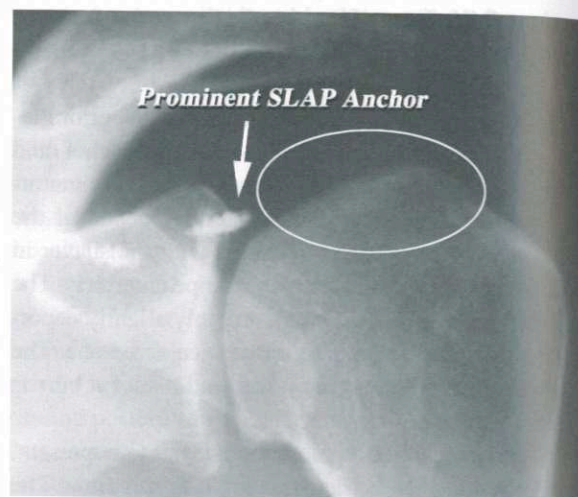


Fig. 11.12 An anterior-posterior radiograph showing a proud metal SLAP anchor. The circle highlights the subsequent iatrogenic chondral and humeral head injury

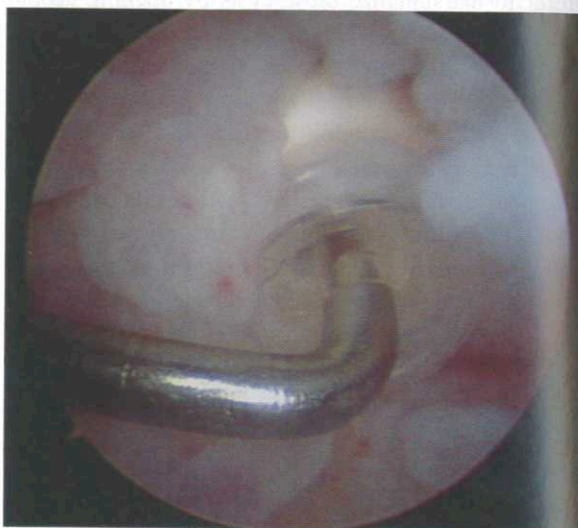

Fig. 11.13 A probe is placed on a proud bioabsorbable SLAP tack resulting in painful synovitis

the sutures are tested for security by gently pulling on them from outside the ASP.

It is important to ensure the anchor is properly inserted to the correct depth or entirely within the glenoid bone. Attention to the specific instrument markings will prevent proud anchors, either metal or bioabsorbable, that will result in chondral injury (Fig. 11.12) and painful synovitis (Fig. 11.13).

Suture Management

Use a crochet hook to retrieve the two nonpurple sutures into of the AMG portal (Fig. 11.14). Place the sutures outside the cannula using a switching rod. Next retrieve the two purple-dyed suture limbs into the AMG portal (Fig. 11.15).

Labrum Fixation

Insert a Spectrum (Linvatec Inc, Largo, FL) medium-sized crescent hook loaded with a Shuttle Relay Suture Passer® (Linvatec Inc, Largo, FL) or #1 monofilament

suture through the AS cannula (Fig. 11.16). Using a penetrating-grasping tool to retrieve the suture can damage the biceps and labrum because of the large puncture size of the tool and is not recommended. Puncture the superior labrum on the posterior edge of the center of the biceps attachment at the level of the glenoid. *If the needle passes through the biceps too far lateral it will pull the biceps down medial when the sutures are tied adding abnormal excess tension to the repair.* Pass the needle through the root of the biceps and under the labrum directly in line with the anchor. The Shuttle Relay® is advanced into the joint, retrieved with a grasper, and carried into the AMG cannula. The two purple suture limbs inside the cannula are loaded into the Shuttle® eyelet and carried through the superior labrum into the ASP (Fig. 11.17).

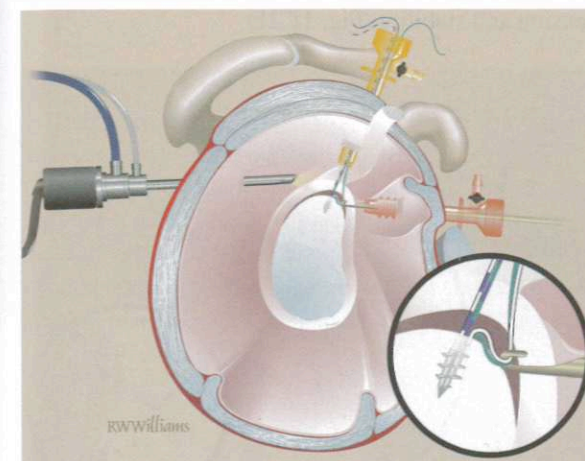


Fig. 11.14 A crochet hook is used to retrieve the nonpurple suture limbs, which are placed outside the AMG cannula

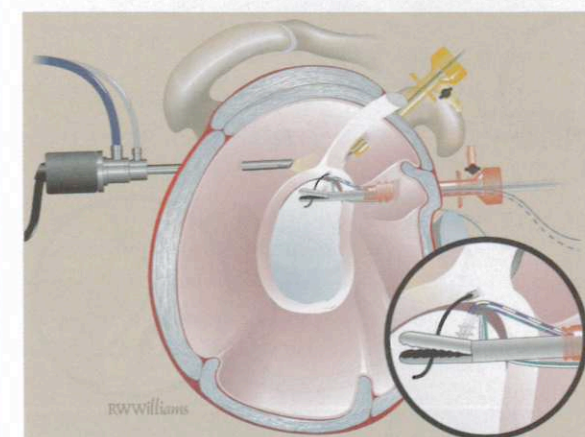


Fig. 11.16 A Spectrum (Linvatec Inc, Largo, FL) medium-sized crescent is used to puncture the biceps origin centrally and pass a shuttle that is retrieved from the AMG cannula

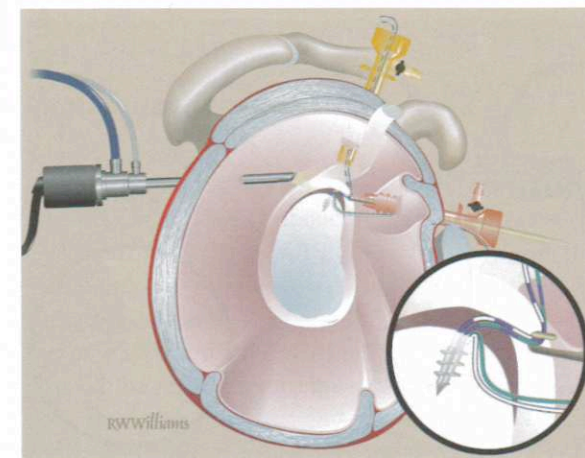


Fig. 11.15 The purple suture limbs are then retrieved and left in the AMG cannula

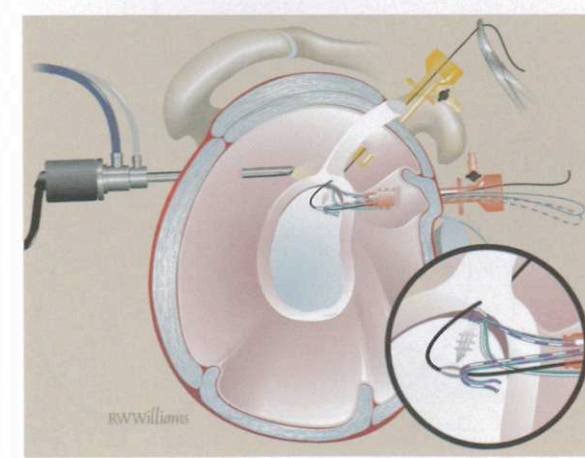


Fig. 11.17 The shuttle carries the purple suture limbs from the AMG cannula into the ASP cannula

Next, the purple-white suture is removed from the ASP into the AMG cannula with a crochet hook *anterior* to biceps tendon. This will avoid tangling the white purple suture when tying the green sutures. Retrieve the green-green suture into the ASP posterior to the biceps tendon using a crochet hook (Fig. 11.18). Pull the purple-green suture (the one through the labral tissue) to make it the shorter limb, and use it as the initial post strand. Tie the green suture using a sliding/locking knot and three alternating half-hitches (Fig. 11.19).

When tying the sutures, it is important not to use too much force. Strong suture material will not likely break but the anchor can be pulled out and the labral tissue can be damaged or strangled. Moderate tension that is

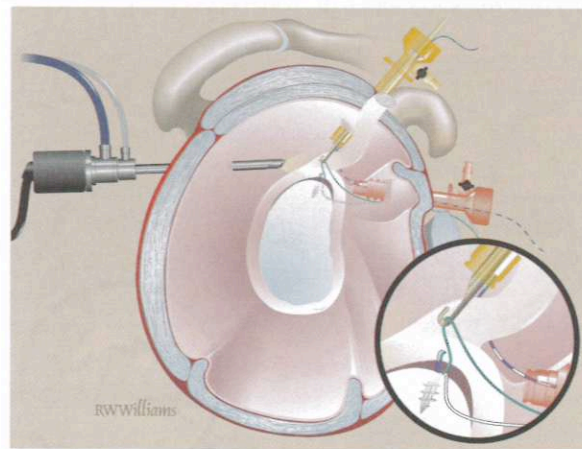


Fig. 11.18 A crochet hook has passed the purple-white suture into the AMG portal while the green suture limb is retrieved posterior to the biceps into the ASP cannula

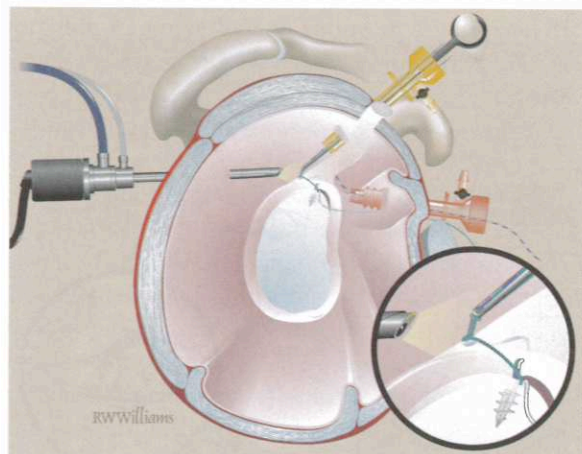


Fig. 11.19 The posterior or green sutures are tied securing the biceps anchor to the glenoid posteriorly. The purple-green suture should be the post

adequate to hold the labrum to the prepared bone is all that is needed.

The purple color scheme facilitates suture management and proper knot tying. The purple sutures are on the tissue or glenoid-labrum side while the nonpurple sutures are toward the glenohumeral joint side. *The purple sutures are used as the posts for knot tying, ensuring that the knots will be behind the labrum and not located near the glenohumeral joint preventing any cartilage irritation.*

Retrieve both limbs of the white suture anterior to the biceps into the AS cannula using a crochet hook (Fig. 11.20). Pull the suture so that the purple-white strand is the shorter limb and tie it using a sliding knot and alternating half-hitches. Evaluate the repair by pulling on the biceps tendon with a probe checking for tension and stability (Fig. 11.21).

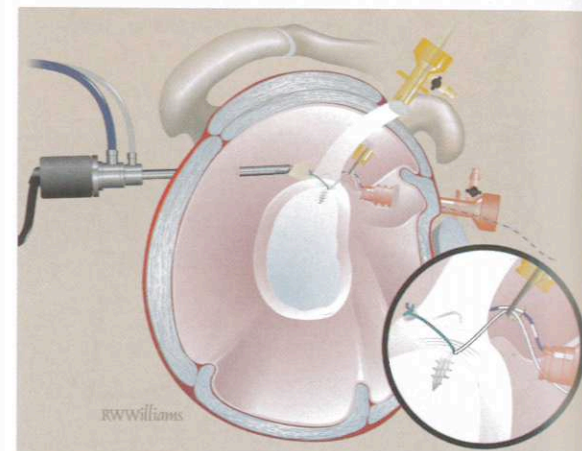


Fig. 11.20 The white sutures are then retrieved anteriorly to the biceps anchor and tied

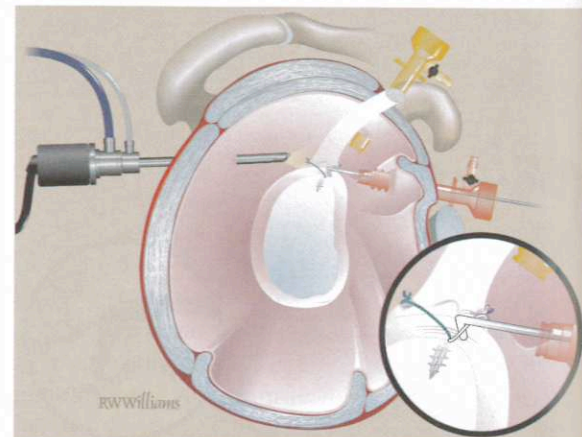


Fig. 11.21 The final SLAP repair has a firmly secured biceps anchor that should be tested with a probe

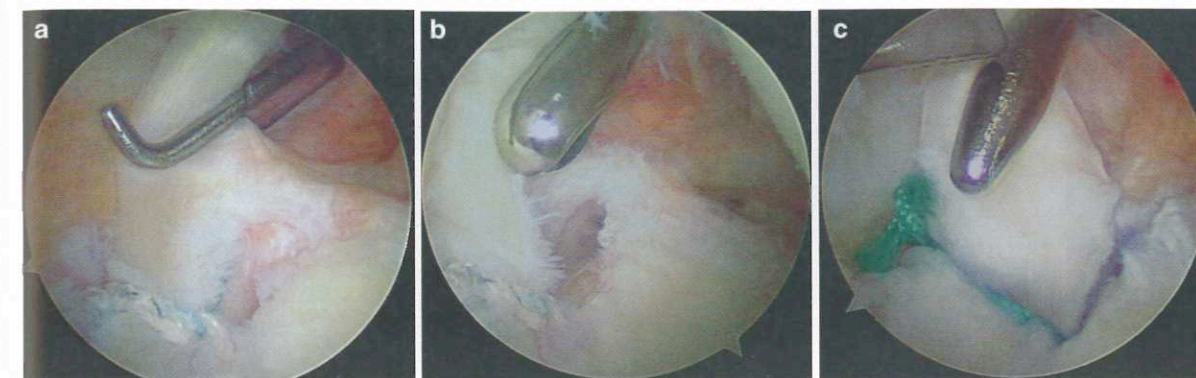


Fig. 11.22 A painful failed SLAP repair and subsequent revision. (a) One suture anchor was previously placed posterior to the biceps anchor origin at an outside institution. (b) The SLAP repair

is inadequate and does not firmly secure the biceps anchor. (c) A new double loaded anchor was placed anterior to the previous anchor at the biceps origin and firmly secures the biceps anchor

Improper anchor placement or anchors that are too anterior or too posterior will not provide central fixation of the biceps anchor to the glenoid. These repairs will often continue to be problematic for patients and need to be revised. The biceps anchor continues to be unstable and is painfully tethered (Fig. 11.22). Proper anchor placement is dependent on portal placement and punch orientation.

Closure

The portals are closed with a single 3-0 subcutaneous stitch supplemented with a Steri-strip. A sterile dressing is applied.

Immobilization

The arm is supported in an UltraSling in 15° external rotation and slight abduction (DJ Orthopedics, Carlsbad, CA). *This position has been useful for preventing the complication of internal rotation contracture and stiffness that previously often resulted from the standard internal rotation brace or sling.* The arm can be removed for elbow, wrist, and hand exercises throughout the day, and pendulum exercises are encouraged three times a day for 4 weeks. Physical therapy begins at 4 weeks and progresses to full activities after 4 months.

Intraoperative Complications and Revision Surgery

The most important aspect for dealing with complications is avoidance of them in the first place. Following the outline above will insure that the lesion is properly secured to bone using the least number of anchors needed (Fig. 11.23). Occasionally, things do go wrong

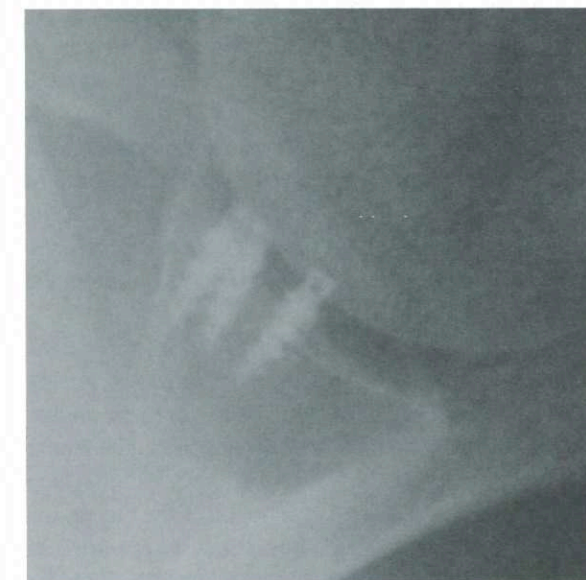

Fig. 11.23 An axillary radiograph revealing multiple, ineffective, anteriorly placed anchors for a SLAP repair. One double loaded anchor correctly placed at the biceps origin is sufficient for a type II SLAP repair

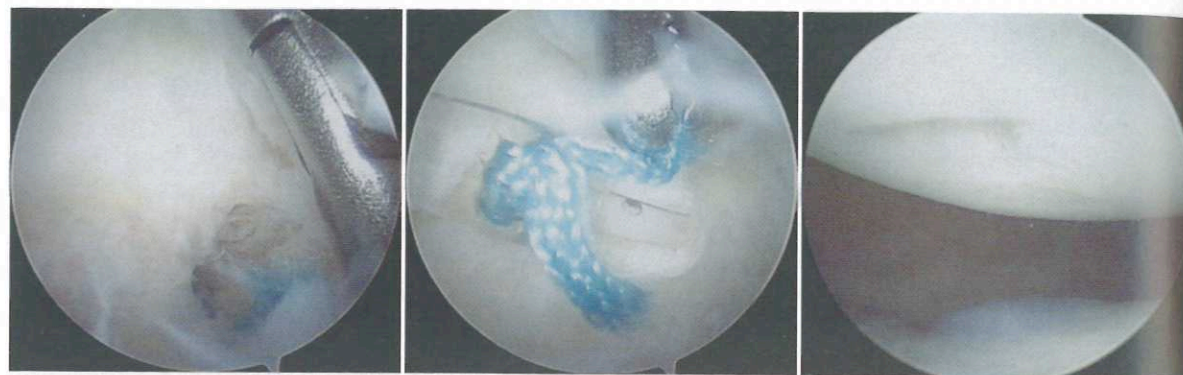

Fig. 11.24 A proud, failed SLAP anchor is removed with a grasper. Note the chondral damage on the humeral head

and the surgeon must be prepared to deal with the situations when they arise.

Sutures unloading or breaking before knots are tied: if a 4 mm metal anchor is used as described above, it can be removed by reloading the remaining suture (if present) into the screw driver and following the suture to the anchor. The orientation seating line on the driver must be aligned with the anchor eyelet and carefully seated over the anchor hub. The anchor can be removed simply by unscrewing it and retrieving it into the AS cannula. If both sutures are broken, it is advised to use an anchor retriever. This is a sheath made by the Linvatec (Largo, FL) company that has an internal reverse thread. The screwdriver is passed inside the retriever, and the anchor is unscrewed and locks into the thread of the retriever. If no retriever is available for the anchor, great care must be taken not to dislodge the loose anchor and lose it in the joint. In that case it should be loosened only half way and the screw driver removed. An arthroscopic grasper can be inserted into the AS cannula and used to complete the removal (Fig. 11.24).

In some cases, the SLAP lesion fails to heal and the anchor is too tightly in-grown in the bone to be readily removed. The bone anterior and posterior to the anchor can be debrided, and two additional single suture anchors can be inserted on either side. Simple loop stitches are passed around the corners of the biceps and labrum shoulders and tied. It is difficult to remove an old anchor unless one has access to the Shoulder Rescue Plug® system from OBI/S&N. (Smith and Nephew, Andover, MA.) This product has a coring tool that can remove the anchor leaving a clean socket

in the bone. A synthetic bone dowel of OBI material (Smith and Nephew, Andover, MA) can be inserted to fill the socket and another anchor then inserted adjacent to the plug.

Additional SLAP Repair Thoughts

There are reports in the literature regarding single portal SLAP repair techniques.^{53,54} Single portal SLAP repair is possible with one ASP. However, these techniques can easily lead to suture tangling. One author reports percutaneous spinal needle retrieval of 1 set of sutures, which acts essentially as a "mini" AMG portal.⁵⁴ However, we feel that creation of a standard AMG portal greatly facilitates suture management and subsequently prevents tangling, minimizes operative time with minimal morbidity, especially for the arthroscopic surgeon who infrequently performs these surgeries.

Type II SLAP lesions are treated as above. SLAP type III and IVs are typically debrided. If these lesions have unstable biceps anchors, then the bucket handle tear is removed and the anchor fixed as above. We have on occasion repaired the bucket handle if the torn labrum may have functional importance. This occasionally occurs in instability patients with a middle glenohumeral ligament that originates from the superior labrum (Fig. 11.25). In these instances, we have removed the posterior bucket handle tear and fixed the residual anterior labrum with associated middle glenohumeral ligament back to the glenoid.

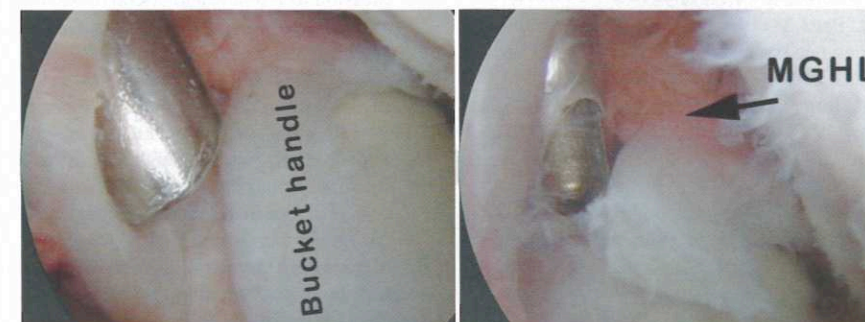

Fig. 11.25 A type III SLAP tear with bucket handle component. The middle glenohumeral ligament originates from the anterior labrum which was retained and fixed to the glenoid in this instability patient

Postoperative Considerations and Rehabilitation

A common problem early in the course of SLAP treatment has been postoperative capsular adhesions. SLAP repair fixes the loose superior labrum along with its superior and middle glenohumeral ligament attachments. If the arm is held in a regular sling or shoulder immobilizer in a position of internal rotation, these tissues along with the traumatized rotator interval tissues will scar, thereby restricting external rotation. It is now possible to avoid this problem by treating the shoulder in an external rotation brace. The brace is worn for 3 weeks but the patient has to remove it for gentle pendulum exercises, and elbow, wrist, and hand exercises, immediately postoperatively. The shoulder should be protected from excess stress on the biceps tendon for 12 weeks. Progressive resistance exercises are allowed at 6 weeks. *Aggressive postoperative rehabilitation too early can result in repair failure.* Vigorous throwing or strenuous lifting is allowed after 4 months if there are no limitations on motion and the patient is asymptomatic.

References

1. Snyder S, Karzel R, Del Pizzo W et al (1990) SLAP lesions of the shoulder. *Arthroscopy* 6:274-49
2. Snyder S, Banas M, Karzel R (1995) An analysis of 140 injuries to the superior glenoid labrum. *J Shoulder Elbow Surg.* 4:243-8
3. Handelberg F, Willems S, Shahabpour M et al (1998) SLAP lesions: A retrospective multicenter study. *Arthroscopy.* 14:856-62
4. Andrews J, Carson W Jr, McLeod W (1985) Glenoid labrum tears related to the long head of the biceps. *Am J Sports Med.* 13:337-41
5. Kumar V, Satku K, Balasubramaniam P (1989) The role of the long head of biceps brachii in the stabilization of the head of the humerus. *Clin Orthop Relat Res.* 244:172-5
6. Itoi E, Kuechle D, Newman S et al (1993 Jul) Stabilising function of the biceps in stable and unstable shoulders. *J Bone Joint Surg Br* 75(4):546-50
7. Gowan I, Jobe F, Tibone J et al (1987) A comparative electromyographic analysis of the shoulder during pitching. Professional versus amateur pitchers. *Am J Sports Med.* 15:586-90
8. Glousman R, Jobe F, Tibone J et al (1988) Dynamic electromyographic analysis of the throwing shoulder with glenohumeral instability. *J Bone Joint Surg Am.* 70:220-26
9. Rodosky M, Harner C, Fu F (1994) The role of the long head of the biceps muscle and superior glenoid labrum in anterior stability of the shoulder. *Am J Sports Med.* 22:121-30
10. Pagnani M, Deng X, Warren R et al (1995) Effect of lesions of the superior portion of the glenoid labrum on glenohumeral translation. *J Bone Joint Surg Am.* 77:1003-10
11. Mileski R, Snyder S (1998) Superior labral lesions in the shoulder: pathoanatomy and surgical management. *J Am Acad Orthop Surg.* 6:121-31
12. Prodromos C, Ferry J, Schiller A et al (1990) Histological studies of the glenoid labrum from fetal life to old age. *J Bone Joint Surg Am.* 72:1344-48
13. Smith D, Chopp T, Aufdemorte T et al (1996) Sublabral recess of the superior glenoid labrum: study of cadavers with conventional nonenhanced MR imaging, MR arthrography, anatomic dissection, and limited histologic examination. *Radiology* 201:251-6
14. Cooper D, Arnoczky S, O'Brien S et al (1992) Anatomy, histology, and vascularity of the glenoid labrum. An anatomical study. *J Bone Joint Surg Am.* 74:46-52

15. Huber W, Putz R (1997) Periarticular fiber system of the shoulder joint. *Arthroscopy* 13:680-91
16. Pal G, Bhatt R, Patel V (1991) Relationship between the tendon of the long head of biceps brachii and the glenoid labrum in humans. *Anat Rec*. 229:278-80
17. Vangsness C Jr, Jorgenson S, Watson T et al (1994) The origin of the long head of the biceps from the scapula and glenoid labrum. An anatomical study of 100 shoulders. *J Bone Joint Surg Br* 76:951-4
18. Snyder S (2003) Superior labrum, anterior to posterior lesions of the shoulder. In: Snyder SJ (ed) *Shoulder Arthroscopy*. Lippincott Williams and Wilkins, Philadelphia, pp 147-65
19. Williams M, Snyder S, Buford D Jr (1994) The Buford complex-the "cord-like" middle glenohumeral ligament and absent anterosuperior labrum complex: A normal anatomic capsulolabral variant. *Arthroscopy* 10:241-7
20. Rao A, Kim T, Chronopoulos E et al (2003) Anatomical variants in the anterosuperior aspect of the glenoid labrum: A statistical analysis of seventy-three cases. *J Bone Joint Surg Am*. 85:653-9
21. Panossian V, Mihata T, Tibone J et al (2005) Biomechanical analysis of isolated type II SLAP lesions and repair. *J Shoulder Elbow Surg*. 14:529-34
22. Morgan C, Burkhart S, Palmeri M et al (1998) Type II SLAP lesions: three subtypes and their relationships to superior instability and rotator cuff tears. *Arthroscopy* 14:553-65
23. Maffet M, Gartsman G, Moseley B (1995) Superior labrum-biceps tendon complex lesions of the shoulder. *Am J Sports Med*. 23:93-8
24. Barber A, Field L, Ryu R (2007) Biceps tendon and superior labrum injuries: decision-marking. *J Bone Joint Surg Am*. 89:1844-55
25. Nam E, Snyder S (2003) The diagnosis and treatment of superior labrum, anterior and posterior (SLAP) lesions. *Am J Sports Med*. 31:798-810
26. Burkhart S, Morgan C (1998) The peel-back mechanism: Its role in producing and extending posterior type II SLAP lesions and its effect on SLAP repair rehabilitation. *Arthroscopy*. 14:637-40
27. Powell S, Nord K, Ryu R (2004) The diagnosis, classification, and treatment of SLAP lesions. *Oper Tech Sports Med*. 12:99-110
28. McFarland E, Kim T, Savino R (2002) Clinical assessment of three common tests for superior labral anterior-posterior lesions. *Am J Sports Med*. 30:810-5
29. Bey M, Elders G, Huston L et al (1998) The mechanism of creation of superior labrum, anterior, and posterior lesions in a dynamic biomechanical model of the shoulder: The role of inferior subluxation. *J Shoulder Elbow Surg*. 7:397-401
30. Clavert P, Bonnomet F, Kempf J, Clavert P, Bonnomet F, Kempf J et al (2004) Contribution to the study of the pathogenesis of type II superior labrum anterior-posterior lesions: a cadaveric model of a fall on the outstretched hand. *J Shoulder Elbow Surg* 13:45-50
31. Burkhart S, Morgan C, Kibler W (2003) The disabled throwing shoulder: spectrum of pathology Part I: pathoanatomy and biomechanics. *Arthroscopy*. 19:404-20
32. O'rien S, Pagnani M, Fealy S et al (1998) The active compression test: a new and effective test for diagnosing labral tears and acromioclavicular joint abnormality. *Am J Sports Med*. 26:610-13
33. Kim S, Ha K, Ahn J et al (2001) Biceps load test II: A clinical test for SLAP lesions of the shoulder. *Arthroscopy*. 17:160-4
34. Kim S, Ha K, Han K (1999) Biceps load test: A clinical test for superior labrum anterior and posterior lesions in shoulders with recurrent anterior dislocations. *Am J Sports Med*. 27:300-3
35. Stetson W, Templin K (2002) The crank test, the O'Brien test, and routine magnetic resonance imaging scans in the diagnosis of labral tears. *Am J Sports Med*. 30:806-9
36. Kibler W (1995) Specificity and sensitivity of the anterior slide test in throwing athletes with superior glenoid labral tears. *Arthroscopy*. 11:296-300
37. Liu S, Henry M, Nuccion S (1996) A prospective evaluation of a new physical examination in predicting glenoid labral tears. *Am J Sports Med*. 24:721-5
38. Jee W, McCauley T, Katz L et al (2001) Superior labral anterior posterior (SLAP) lesions of the glenoid labrum: Reliability and accuracy of MR arthrography for diagnosis. *Radiology*. 218:127-32
39. Kaplan P, Helms C, Dussault R et al (2001) Shoulder. In: Kaplan PA, Helms CA, Dussault R, Anderson MW, Major NM (eds) *Musculoskeletal MRI*. WB Saunders, Philadelphia, pp 175-223
40. Reuss B, Schwartzberg R, Zlatkin M et al (2006) Magnetic resonance imaging accuracy for the diagnosis of superior labrum anterior-posterior lesions in the community setting: Eighty-three arthroscopically confirmed cases. *J Shoulder Elbow Surg*. 15:580-5
41. Tuite M, Cirillo R, De Smet A et al (2000) Superior labrum anterior-posterior (SLAP) tears: Evaluation of three MR signs on T2-weighted images. *Radiology*. 215:841-5
42. Jin W, Ryu K, Kwon S et al (2006) MR arthrography in the differential diagnosis of type II superior labral anteroposterior lesion and sublabral recess. *AJR Am J Roentgenol*. 187:887-93
43. Bencardino J, Beltran J, Rosenberg ZS et al (2000) Superior labrum anterior-posterior lesions: diagnosis with MR arthrography of the shoulder. *Radiology*. 214:267-71
44. Westerheide K, Dopirak R, Karzel R et al (2006) J Suprascapular nerve palsy secondary to spinoglenoid cysts: Results of arthroscopic treatment. *Arthroscopy* 22:721-7
45. Westerheide K, Karzel R (2003) Ganglion cysts of the shoulder: technique or arthroscopic decompression and fixation of associated type II superior labral anterior to posterior lesions. *Orthop Clin North Am*. 34:521-8
46. Burkhart S, Morgan C, Kibler W (2003) The disabled throwing shoulder: Spectrum of pathology Part II: Evaluation and treatment of SLAP lesions in throwers. *Arthroscopy* 19:531-9

Editors' Comments (Slap Repairs)

A single anterosuperior portal can be utilized if one is comfortable with using a "crabclaw" type device to untangle sutures that will inevitably tangle.

If a suture breaks while tying and a plastic or bioabsorbable anchor has been used, the same pilot hole may be utilized and redrilled with placement of the same sized anchor. If the anchor then pulls out upon insertion, be prepared to have a larger anchor available for insertion. Thus, for a 3 mm suture anchor that pulls out, a 4.5 mm anchor can be utilized as a bail out.

There seems to be more emphasis of late on reducing the peel back phenomenon of SLAP tears by ensuring that the posterosuperior aspect of the SLAP is addressed.

Examine for associated anteroinferior and/or posteroinferior labral pathology.

47. Yoneda M, Hirooka A, Saito S et al (1991) Arthroscopic stapling for detached superior glenoid labrum. *J Bone Joint Surg Br*. 73:746-50
48. Field L, Savoie FIII (1993) Arthroscopic suture repair of superior labral detachment lesions of the shoulder. *Am J Sports Med*. 21:783-90
49. Burbank S, Snyder S (2007). Biomechanical analysis of SLAP repair techniques and meta-analysis of literature. Hospital for Special Surgery and Southern California Orthopedic Institute. Unpublished data.
50. Tyorkin M, Snyder S (2008) Arthroscopic Repair of SLAP lesions by the single anchor double suture technique. In: Cole B, Cole B, Sekiya M (eds) *Surgical techniques of the shoulder, elbow and knee in sports medicine*. Elsevier, New York
51. Bigliani L, Dalsey R, McCann P et al (1990) An anatomical study of the suprascapular nerve. *Arthroscopy*. 6:301-5
52. Warner J, Krushell R, Masquelet A et al (1992) Anatomy and relationships of the suprascapular nerve: Anatomical constraints to mobilization of the supraspinatus and infraspinatus muscles in the management of massive rotator-cuff tears. *J Bone Joint Surg Am*. 74:36-45
53. Buess E, Schneider C (2006) Simplified single-portal V-shaped SLAP repair. *Arthroscopy* 22(680):e1-4
54. Kim K, Rhee K, Shin H et al (2008) Modified single-portal type II SLAP repair. *Arch Orthop Trauma Surg* 128(11):1251-4